

1. Upward movement of the thyroid gland is prevented due to?

- a) Berry ligament
- b) Pretracheal fascia
- c) Sternothyroid muscle
- d) Thyrohyoid membrane

Correct Answer - B

Ans: B. Pretracheal fascia

The thyroid gland is covered by a thin fibrous capsule, which has an inner and an outer layer. The inner layer extrudes into the gland and forms the septum that divides the thyroid tissue into microscopic lobules.

The outer layer is continuous with the pretracheal fascia, attaching the gland to the cricoid and thyroid cartilages via a thickening of the fascia to form the posterior suspensory ligament of the thyroid gland also known as Berry's ligament. This causes the thyroid to move up and down with the movement of these cartilages when swallowing occurs.

**Gray's Anatomy: The Anatomical Basis of Clinical Practice, 41e
,Page no 470**

2. The reason for the long left recurrent laryngeal nerve is due to the persistence of which arch artery?

a) 3rd arch

b) 4th arch

c) 5th arch

d) 2nd arch

Correct Answer - B

Ans: B. 4th arch

Left RLN winds around the arch of aorta

Arch of aorta is derived from the 4th arch

Langmans Medical Embryology 13th edition (Page no 88,239)

3. Ligation of the hepatic artery will impair blood supply in

a) Right gastric and Right gastroepiploic artery

b) Right gastric and Left gastric artery

c) Right gastroepiploic and short gastric vessels

d) Right gastric and short gastric vessels

Correct Answer - A

Ans: A. Right gastric and Right gastroepiploic artery

The right gastric artery is a branch of the common hepatic artery

The right gastroepiploic artery is a branch of the gastroduodenal artery which is a branch of the common hepatic artery

The left gastric artery is a branch of the celiac trunk

Short gastric vessels arise from the splenic artery

Gray's Anatomy: The Anatomical Basis of Clinical Practice, 41st Edition (Page nos 1116 and 1117)

4. Wolffian duct remnant in female is

a) Pouch of Douglas

b) Uterovesical pouch

c) Gartner's cyst

d) Broad ligament

Correct Answer - C

Ans: C. Gartner's cyst

Gartner's cysts, sometimes incorrectly referred to as vaginal inclusion cysts, are the most common benign cystic lesions of the vagina.

They represent embryological remnants of the caudal end of the mesonephric(Wolffian) duct.

Gartner's ducts are found in about 25% of adult women. Almost one percent of these ducts evolve into Gartner's duct cyst.

Ref: A case of Gartner's cyst of vagina, J. Anesth Crit care Open Access, 2017, 00259.

5. Nerve supply of the extraocular muscles is constituted by all except

a) Ophthalmic nerve

b) Oculomotor nerve

c) Trochlear nerve

d) Abducent nerve

Correct Answer - A

Ans: A. Ophthalmic nerve

Lateral rectus is supplied by 6th cranial nerve(abducent nerve)

Superior rectus is supplied by 4th cranial nerve (trochlear nerve)

All of the remaining extraocular muscles are supplied by the oculomotor nerve. The ophthalmic nerve is a branch of the trigeminal nerve and is purely sensory in nature.

BDC 7th edition, volume 3, pg no. 215.

6. Claudication due to popliteal femoral incompetence is primarily seen in

a) Thigh

b) Calf

c) Buttocks

d) Feet

Correct Answer - B

Ans: B. Calf

Calf

Aorta and Common Iliac- Buttocks

Femoral Artery- Thigh

Superficial femoral artery- Calf and popliteal artery

Posterior tibial Artery- Feet

BDC 7th edition, volume 2, page no 137.

7. Which muscle is paralyzed if there is hyperextension of metacarpophalangeal joint and flexion of the interphalangeal joint?

a) Extensor digitorum

b) Interossei and lumbricals

c) Adductor pollicis

d) Pronator quadratus muscle

Correct Answer - B

Ans: B. Interossei and lumbricals

Hyperextension of metacarpophalangeal joint and flexion of the interphalangeal joint is due to palsy of lumbricals and interossei muscles.

The action of Lumbricals: Flexion of MCP, Extension of IP joint

The action of Palmar interossei: Adduction of fingers

The action of Dorsal interossei: Abduction of fingers

Ref: BDC, 7th edition, volume 1, pg no. 163.

8. Tumour of the uncinate process of the pancreas will compress which artery

- a) Portal vein
- b) Superior mesenteric artery
- c) Inferior mesenteric artery
- d) Common hepatic artery

Correct Answer - B

Ans: B. Superior mesenteric artery

The superior mesenteric artery passes anterior to the uncinate process

Posteriorly, the uncinate process is related to aorta.

Ref: BDC , 7th edition, vol 2, page- 328.

9. A boy met with a motorbike accident. CT brain shows injury to the posterior end of the superior temporal gyrus. He is likely to suffer from

a) Fluent aphasia

b) Non-fluent aphasia

c) Conduction aphasia

d) None of the above

Correct Answer - A

Ans: A. Fluent aphasia

Fluent aphasia

Lesions in the posterior portion of the left STG were associated with the loss of the ability to comprehend and produce spoken words which are called as "fluent aphasia"

BDC 7th edition, volume 4, page no 129.

10. A 65-year-old lady presents with a vascular injury to the inferior frontal gyrus. Which functional area would mostly be affected

a) Visual

b) Auditory

c) Wernicke

d) Motor speech

Correct Answer - D

Ans: D. Motor speech

Motor speech defect is also called apraxia of speech.

Injury to the Broca's area/left inferior frontal gyrus causes motor speech defect.

BDC 7th edition, volume 4, page no 129.

11. Where is the highest oxygen concentration presents in fetal circulation

a) SVC

b) IVC

c) Right ventricle

d) Aorta

Correct Answer - B

Ans: B. IVC

Highly oxygenated blood from the placenta is carried to the fetus **by the umbilical vein**, which is shunted to the inferior vena cava.

Nelson Textbook of Pediatrics 20th Edition (Page no 2161)

12. When the value of V/q is infinity, it means?

- a) No O₂ goes from alveoli to blood and no CO₂ goes from blood to alveoli
- b) Dead space
- c) The PO₂ of alveolar air is 159mmHg and PCO₂ is 40mmHg
- d) Partial pressure of O₂ and CO₂ are equal

Correct Answer - B

Ans: B. Dead space

Dead space

An area with ventilation but no perfusion.

* V/Q undefined, though approaching infinity.

Interpretations of V/Q ratio values:

* Value is 0.8

- Ventilation-Perfusion matching

* If V/Q is > 0.8 –

- This means more ventilation than perfusion.

* If V/Q is < 0.8 –

- V/Q mismatch

Ref: Arvind Arora review book of physiology (p. 240 - 241)

13. Proteoglycan present in the glomerular basement membrane is?

a) Keratan sulphate 1

b) Keratan sulphate 2

c) Heparan sulphate

d) Chondroitin sulphate

Correct Answer - C

Ans: c. Heparan sulphate

The glomerular membrane (or the filtration barrier) is the filtration surface through which the fluid is filtered out from the blood.

The glomerular membrane (filtration barrier) comprises:

- * The glomerular capillary endothelium.
- * The basement membrane (basal lamina).
- * The Bowman's visceral epithelium (podocytes).
- * Important constituents of glomerular membrane include,
 - Laminin
 - Type 4 collagen
 - Nidogen
 - Proteoglycans - (Heparan sulphate)

Ref: Arvind Arora review book of physiology (p. 371 - 372)

14. 35yr old female was watching TV for long hours with hands under her head. She complains of tingling sensation over her arm. Which type of nerve fibers is most likely to be affected?

a) Fibers

b) B - fibers

c) C - Fibers

d) Sympathetic nerve fibers

Correct Answer - A

Ans: A. Fibers

A-delta	Features: Diameter - 1-5 Myelination - Some myelination Conduction - 5-30	Functions: Pain - - "Fast/Epicritic/First" pain. - Since fibers are relatively fast Temperature Pressure Touch	High susceptible to Pressure
---------	--	--	------------------------------

Ref: Arvind Arora review book of physiology (p. 58 - 59)

15. The reflex in which there is inhibition of gastric emptying when there is acid and hypertonic solution in the duodenum?

a) Enterogastric

b) Gastroileal

c) Gastrocolic

d) Myenteric

Correct Answer - A

Ans: A. Enterogastric

The enterogastric reflex is one of the three extrinsic reflexes of the gastrointestinal tract, the other two being the gastroileal reflex and the gastrocolic reflex.

The enterogastric reflex is stimulated by duodenal distension. It can also be stimulated by a pH of 3-4 in the duodenum and by a pH of 1.5 in the stomach.

The main neural influence in gastric emptying is thought to be mediated via an inhibitory mechanism referred to as the enterogastric reflex. Fats, fatty acids, soaps, protein digestive products, acids, and hypertonic solutions in the small intestine inhibit motility.

Ref: [https://www.gastrojournal.org/article/S0016-5085\(75\)80295-2/pdf](https://www.gastrojournal.org/article/S0016-5085(75)80295-2/pdf)

16. In multiple sclerosis, slow conduction of motor and the sensory pathways is due to?

a) Defect in the node of Ranvier

b) Loss of myelin sheath

c) Leaking of sodium channels

d) Leaking calcium channels

Correct Answer - B

Ans: B. Loss of myelin sheath

Multiple Sclerosis (MS) is a disabling progressive neurological disorder

The pathophysiology of MS results in disruption or loss of axonal myelin in the central nervous system (CNS), leading to the formation of scar tissue (sclerosis).

Demyelination produces alterations in saltatory conduction, slowed conduction velocity, and a predisposition to conduction block

Ref: <https://www.physiology.org/doi/pdf/10.1152/japplphysiol.004>

17. Which of the following clotting factor in a patient on Warfarin therapy, would have decreased gamma carboxyglutamate residue?

a) Factor 2

b) Factor 11

c) Tissue factor

d) Factor 5

Correct Answer - A

Ans: A. Factor 2

- Vitamin K is a cofactor for the enzymatic conversion of glutamic acid (Glu) residues to gamma-carboxyglutamic acid (GLA) in vitamin K-dependent proteins, via the endoplasmic reticulum resident vitamin K-dependent gamma-glutamyl carboxylase.
- This carboxylase activity is found in essentially all mammalian tissues, and its reaction product, Gla, has been observed in both vertebrates and invertebrates; both play an important biological role in protein function.
- Vitamin K–dependent clotting factor deficiency (VKCFD) is a rare autosomal recessive bleeding disorder that often presents with severe hemorrhage during infancy.
- A rare inherited form of defective γ -carboxylation resulting in the early onset of bleeding was first described by McMillan and Roberts in 1966 and subsequently has been termed *vitamin K–dependent clotting factor deficiency* (VKCFD).
- Combined deficiency of vitamin K–dependent clotting factors II, VII, IX, and X (and proteins C, S, and Z) is usually an acquired clinical problem, often resulting from liver disease, malabsorption, or warfarin overdose.

•

18. Blood stored in citrate-phosphate-dextrose is better for hypoxic patients than acidic-citrate-dextrose because?

a) It has less P_{50}

b) It is less acidic

c) The fall in 2, 3 DPG is less

d) None of the above

Correct Answer - C

Ans: C. The fall in 2, 3 DPG is less

- The infusion of ACD blood caused P_{50} and 2,3-DPG concentration to decrease significantly.
- The infusion of blood stored in citrate phosphate dextrose (**CPD**) did not significantly increase the oxygen affinity.
- To compensate for the increased oxygen affinity, there must be a rise in cardiac output or more likely a decrease in venous PO_2 .
- The transfusion of CPD blood, therefore, is more favorable in terms of oxygen supply, particularly in patients who have had cardiac surgery.

19. Which of the following is referred to as the "Window of the limbic system"?

a) Hypothalamus

b) Amygdala

c) Hippocampus

d) Thalamus

Correct Answer - B

Ans. B i.e. Amygdala.

* The amygdala has been called the "window" through which the limbic system sees the place of the person in the world.

* The amygdala receives neuronal signals from all portions of the limbic cortex, as well as from the neocortex of the temporal, parietal, and occipital lobes, especially from the auditory and visual association areas.

20. Cerebral blood flow is regulated by all except:

a) Blood pressure

b) Arterial PCO_2

c) Potassium ions

d) A & C

Correct Answer - D

Ans. A & C. i.e. Blood pressure & Potassium ions

The total cerebral blood flow is held constant in face of considerable changes in the systemic blood pressure (60-150 mm Hg)". -

Principles of medical physiology.

"Cerebral blood flow is not affected over a fairly wide variation in arterial blood pressure". - RK Marya.

Regulation of cerebral bloodflow:

1) Autoregulation:- Due to the inherent property of blood vessels, explained by myogenic theory.

2) Metabolic regulation: CBF varies directly with metabolic activity.

Factors affecting regulation are PCO_2 , PO_2 , K^+ , and adenosine.

Among this PCO_2 is the most important one.

3) Sympathetic innervation:- Important only in cases with very severe elevation of BB e.g. in very strenuous exercises.

4) Intracranial pressure:- By Cushing reflex.

5) Others: Blood viscosity.

21. Hepcidin inhibits ?

- a) Absorption of cobalamine
- b) Transfer of iron into enterocytes
- c) Folic acid synthesis
- d) Respiratory oxidase

Correct Answer - B

Ans. is 'b' i.e., Transfer of iron into enterocytes

- Hepcidin is an iron metabolism regulatory hormone that inhibits iron absorption (transfer of iron into enterocytes).
- **Ascorbic acid (vitamin C)** forms soluble complexes with iron and **reduces iron from the ferric to the ferrous state**, thereby **enhancing iron absorption**.
- **Tannins**, present in tea, form insoluble complexes with iron and **lower its absorption**.

22. Which of the following technique is used to study current flow across a single ion channel?

a) Patch clamp

b) Voltage clamp

c) Iontophoresis

d) Galvanometry

Correct Answer - A

Ans. a. Patch-clamp

- Patch-clamp is a technique to record ion current flow through a single protein channel.
- The patch-clamp technique is a laboratory technique in electrophysiology, that allows the study of single or multiple ions channels in cells.
- The technique can be applied to a wide variety of cells but is especially useful in the study of excitable cells such as neurons, cardiomyocytes, muscle fibers, and pancreatic beta cells.
- It can also be applied to the study of bacterial ion channels especially prepared giant spheroplasts.
- In the patch-clamp experiment, a small pipette is carefully maneuvered to seal off a portion of a cell membrane. The pipette has an electrode bathed in an appropriate solution that allows for the recording of electrical changes through any pore in the membrane.

23. A 4-year-old boy of a first-degree consanguineous couple was noted by the parents to have darkening of the urine to an almost black color when it was left standing. He has a normal sibling, and there are no other medical problems. Growth and development to date are normal. Which of the following is most likely to be elevated in this patient?

a) Methylmalonate

b) Homogentisate

c) Phenylpyruvate

d) α -Ketoisovalerate

Correct Answer - B

Ans: B. Homogentisate.

* Alkaptonuria is a rare metabolic disease involving a deficiency in homogentisic acid oxidase, and the subsequent accumulation of homogentisic acid in the urine, which turns dark upon standing.

* The elevation of

→ methylmalonate (due to methylmalonyl CoA mutase deficiency),

→ Phenylpyruvate (due to phenylalanine hydroxylase deficiency),

→ α -ketoisovalerate (due to branched-chain α -keto acid dehydrogenase deficiency),

→ Homocysteine (due to cystathionine β -synthase deficiency)

* All of these are inconsistent with a healthy child with a darkening of

24. Which of the following is true about different structures of protein?

- a) Secondary structure is the three-dimensional structure of protein
- b) Secondary structure is stabilized by disulfide bonds
- c) Primary, secondary and tertiary structures destroyed during denaturation
- d) Secondary and tertiary structure depends on the sequence of amino acids

Correct Answer - D

Ans: D. Secondary and tertiary structure depends on the sequence of amino acids

Explanation

Proteins are arranged in any of the following four structures viz:

* Primary

The sequence of amino acids in a protein is called the primary structure of the protein chain

* Secondary

- The polypeptide backbone does not assume a random three-dimensional structure, but instead generally forms regular arrangements of amino acids that are located near to each other in the linear sequence. The α -helix, β -sheet, and β -bend (β -turn) are examples of secondary structures frequently encountered in proteins.

* Tertiary

- It refers to the three-dimensional arrangement of a polypeptide chain that has assumed its secondary structure. Disulfide bonds

25. The insulin glucagon ratio decreased. The enzyme is active at this time?

a) Glucokinase

b) Hexokinase

c) Phosphofructokinase

d) Glucose 6 phosphatase

Correct Answer - D

Ans. D.Glucose 6 phosphatase

Explanation

Low insulin:glucagon ratio (IGR) stimulates mobilization of stored nutrients, increases glycogenolysis and gluconeogenesis, and promotes the breakdown of adipose tissue into free fatty acids and glycerol.

Decreases Insulin/glucagon ratio shows the fasting stage.

Glucokinase, Hexokinase, and phosphofructokinase are glycolytic.

Only gluconeogenic is glucose 6 phosphatase.

Ref- <https://www.ncbi.nlm.nih.gov/pmc/articles/PMC4801814>

26. Ochronosis is due to the accumulation of?

a) Homogentisic acid

b) Homogentisic acid

c) Xanthurenate

d) Glyoxylate

Correct Answer - A

Ans: A. Homogentisic acid

Alkaptonuria is an autosomal recessive condition due to the deficiency of homogentisate 1,2 dioxygenase. This results in the excretion of homogentisic acid in urine. It is compatible with a fairly normal life.

The only abnormality is the blackening of urine on standing. Homogentisic acid is oxidized by polyphenol oxidase to benzoquinone acetate. It is then polymerized to black colored alkapton bodies.

By the 3rd or 4th decade of life, the patient may develop ochronosis (deposition of alkapton bodies in intervertebral discs, cartilages of nose, pinna of the ear). Black pigments are deposited over the connective tissues including joint cavities to produce arthritis.

No specific treatment is required. But minimal protein intake with phenylalanine less than 500 mg/day is recommended.

Ref- DM Vasudevan- Textbook of biochemistry for medical students, 6th edn, Aromatic Amino Acids, and Amino Acidurias, pg 208.

27. Bilirubin in serum can be measured by

a) Van den Bergh reaction

b) Ehrlich's Reaction

c) Schlesinger's Reaction

d) Fouchet's Reaction

Correct Answer - A

Ans: A. Van den Bergh reaction

Bilirubin is most commonly determined by the van den Bergh reaction, in which diazotized sulfanilic acid reacts with bilirubin to form red azodi pyrroles

These are measured colorimetrically. In aqueous solution, the water-soluble, conjugated bilirubin reacts rapidly with the reagent (within one minute), and is said to be "direct-reacting." The unconjugated bilirubin, which is much less soluble in aqueous solution, reacts more slowly.

However, when the reaction is carried out in methanol, both conjugated and unconjugated bilirubin are soluble and react with the reagent, providing the total bilirubin value. The "indirect-reacting" bilirubin, which corresponds to the unconjugated bilirubin, is obtained by subtracting the direct-reacting bilirubin from the total bilirubin

Note: In normal plasma, only about 4% of the total bilirubin is conjugated or direct-reacting, because most are secreted into bile.

Ref- Lippincott's Illustrated reviews, 5th edition, Conversion of amino acids in specialized products, Pg 285.

28. If a sample of DNA if adenine is 28% what will be the amount of Cytosine present

a) 23%

b) 25%

c) 46%

d) 22%

Correct Answer - D

Ans: D. 22%

The bases of one strand of DNA are paired with the bases of the second strand so that adenine is always paired with thymine and cytosine is always paired with guanine. Therefore, one polynucleotide chain of the DNA double helix is always the complement of the other. Given the sequence of bases on one chain, the sequence of bases on the complementary chain can be determined.

Note: The specific base pairing in DNA leads to the Chargaff Rule: In any sample of dsDNA, the amount of adenine equals the amount of thymine, the amount of guanine equals the amount of cytosine, and the total amount of purines equals the total amount of pyrimidines.

The base pairs are held together by hydrogen bonds: two between A and T and three between G and C (Figure 29.5). These hydrogen bonds, plus the hydrophobic interactions between the stacked bases, stabilize the structure of the double helix.

Ref- lippincott's Illustrated reviews, 5th edition, the structure of DNA, pg 397

29. Which of the following vitamin at higher doses causes cystoid macular edema-

a) Vit A

b) Vit D

c) Vit E

d) Niacin

Correct Answer - D

Ans: D. Niacin

Cystoid macular edema (CME) is a condition that involves the macula, causing painless vision loss.

Niacin (nicotinic acid, vitamin B3, vitamin PP), one component of the dietary supplement taken by the patient, is a vitamin preparation usually used for the treatment of lipid disorders

Fraunfelder et al. reported that 3 g or more per day of nicotinic acid could cause many ocular side effects such as blurred vision, eyelid edema, toxic amblyopia, proptosis, loss of eyelashes or eyebrow, superficial punctate keratitis, and cystoid macular edema, which represents the most serious ocular complications. All these adverse effects are reversible with discontinuation of niacin therapy

Ref- Case Reports in Ophthalmological Medicine, Volume 2013, Article ID 713061, 5 page

30. True statement regarding Huntington's chorea is

- a) There is a loss of function type of mutation
- b) It is an autosomal recessive
- c) It is a trinucleotide repeat expansion type of disorder
- d) Increased number of CAA repeats

Correct Answer - C

Ans: C. It is a trinucleotide repeat expansion type of disorder

Huntington's chorea is an autosomal dominant disorder with an increased number of CAG repeats. Clinically manifested as involuntary jerky movements, mood disturbances and finally severe dementia.

Ref- Lange biochemistry and genetics flash cards, Huntington's disease, pg 161

31. Addition of which Amino Acid will increase UV absorption

a) Tryptophan

b) Leucine

c) Proline

d) Arginine

Correct Answer - A

Ans: A. Tryptophan

Amino Acid Absorb UV Light

- Amino Acids that absorb 250-290 nm (Maximum at 280 nm) UV light are tryptophan, phenylalanine, tyrosine.
- The maximum absorption of UV light is by tryptophan.
- As it absorbs ultraviolet light about ten times more efficiently than phenylalanine or tyrosine, tryptophan makes the major contribution to the ability of most proteins to absorb light in the region of 280 nm.
- Tryptophan and tyrosine absorb UV at approximately 280 nm.
- UV absorption spectroscopy is utilized to measure protein concentration. The absorption spectrum of a protein in the UV wavelength range is the result of absorption of light by the aromatic amino acids (250-320 nm), the disulfide bonds (250-300 nm) and the carbonyl group of the peptide bond (190-210).

Remember

- Aromatic Amino Acids absorb UV Lights
- Amino acids are colourless because they do not absorb visible light.

Ref-Rebecca james-self assessment and review of biochemistry, 3rd edn, Chemistry, and Metabolism of Amino Acids, Pg 7

32. V- Richest source of vitamin B12 ?

a) Meat

b) Green leafy vegetables

c) Corn oil

d) Sunflower oil

Correct Answer - A

Ans: A. Meat

* Vitamin B12 is naturally found in animal products, including fish, meat, poultry, eggs, milk, and milk products.

* Synonyms are cobalamin, extrinsic factor (EF) of Castle and anti pernicious anemia factor. Vitamin B12 is water-soluble, heat stable and red in color. It is satisfied by any of the following groups: cyanide, hydroxyl, adenosyl or methyl.

* Cyanocobalamin- Oral preparations are in this form.

* Hydroxy cobalamin- Injectable preparations are in this form.

* Adenosylcobalamin- This is the major storage form, seen in the liver.

* Methylcobalamin-This is the major form seen in blood circulation as well as in the cytoplasm of cells.

* Vitamin B12 is generally not present in plant foods, but fortified breakfast cereals are a readily available source of vitamin B12 with high bioavailability for vegetarians.

* Rich source of vitamin B12→

- Beef, liver, and chicken.
- Fish and shellfish such as trout, salmon, tuna fish, and clams.
- Fortified breakfast cereal.
- Low-fat milk, yogurt, and cheese.
- Eggs.

33. Which amino acid is used to synthesize Nitric oxide?

a) Glycine

b) Arginine

c) Tyrosine

d) Threonine

Correct Answer - B

Ans: B. Arginine

Nitric oxide is formed from arginine by the enzyme nitric oxide synthase (NOS). It contains heme, FAD, FMN, NADPH, and tetrahydrobiopterin.

Nitric oxide has a very short half-life (3-4 seconds). NO combines with oxygen to form NO₂. These nitrites are excreted through urine. Reacting with hemoglobin, NO is converted to NO₃; and nitrates are also excreted in the urine. The very low quantity of NO is expelled through the lung.

Arginine is a highly basic, semi-essential amino acid. It is glucogenic in nature.

34. True About Noncompetitive antagonist -

a) K_m remains same, V_{max} decreases

b) K_m remains same, V_{max} decreases

c) K_m decreases, V_{max} increases

d) K_m increases, V_{max} increases

Correct Answer - A

Ans: A. K_m remains same, V_{max} decreases

Noncompetitive inhibition occurs when the inhibitor and substrate bind at different sites on the enzyme. The noncompetitive inhibitor can bind either the free enzyme or the ES complex, thereby preventing the reaction from occurring.

Effect on V_{max} : Noncompetitive inhibition cannot be overcome by increasing the concentration of the substrate. Thus, noncompetitive inhibitors decrease the apparent V_{max} of the reaction.

Effect on K_m : Noncompetitive inhibitors do not interfere with the binding of substrate to enzyme. Thus, the enzyme shows the same K_m in the presence or absence of the non-competitive inhibitor.

Effect on Lineweaver-Burk plot: Noncompetitive inhibition is readily differentiated from competitive inhibition by plotting $1/v_o$ versus $1/[S]$ and noting that the apparent V_{max} decreases in the presence of a non-competitive inhibitor, whereas K_m is unchanged

Ref- lippincott's Illustrated reviews, 5th edition, Inhibition of Enzyme Activity, pg 61.

35. Werner syndrome associated with premature aging is caused due to a defect in which of the following?

a) Telomerase

b) Caspase

c) DNA topoisomerase

d) DNA helicase

Correct Answer - D

Ans: D. DNA helicase

Werner syndrome is a human autosomal recessive disorder that displays symptoms of premature aging, including early graying and thinning of hair, wrinkling and ulceration of skin, atherosclerosis, osteoporosis, and cataracts.

In addition, Werner syndrome patients exhibit an increased incidence of diabetes mellitus type 2, hypertension, and are highly disposed to the emergence of benign and malignant neoplasms. Werner syndrome caused by mutation of the *WRN* gene, a member of the RecQ DNA helicase family.

Ref- <https://www.ncbi.nlm.nih.gov/pmc/articles/PMC3237395/>

36. Which of the following dietary fiber is insoluble in water?

a) Pectin

b) Lignin

c) Hemicellulose

d) Cellulose

Correct Answer - B

Ans: B. Lignin

The unavailable or indigestible carbohydrates in the diet are called dietary fiber.

Dietary fiber is necessary to maintain the normal motility of the gastrointestinal tract. They are chiefly-

- Cellulose- Retains water in feces, promotes peristalsis, increases bowel action
- Lignin- Antioxidant, increases bile acid excretion, hypocholesterolemic.
- Pectins- Partially Absorb water, slows esterified gastric emptying, binds bile acids, increases their excretion
- Hemi-cellulose- Retains water in feces, cellulose, increases bile acid and uronic acid excretion.

Ref- DM Vasudevan- Textbook of biochemistry for medical students, 6th edn , Energy Metabolism and Nutrition. Pg 435.

37. According to NCEP-ATP III, which among the following have not been included in metabolic syndrome?

a) High LDL

b) Hypertriglyceridemia

c) Central Obesity

d) Hypertension

Correct Answer - A

Answer- A. High LDL

Metabolic syndrome refers to the co-occurrence of several known cardiovascular risk factors, including insulin resistance, obesity, atherogenic dyslipidemia, and hypertension. These conditions are interrelated and share underlying mediators, mechanisms, and pathways.

Criteria for the Diagnosis of Metabolic Syndrome

- Elevated waist circumference: (For men >90 cm and for women, >80 cm).
- Elevated triglycerides: >150 mg/dL
- Reduced HDL ("good") cholesterol: For men, <40 mg/dL; for women, < 50 mg/dL
- Elevated blood pressure: >130/85 mmHg
- Elevated fasting glucose: >100 mg/dL
- Insulin resistance (hyperinsulinemia)
- Additional parameters include: coagulation abnormalities, hyperuricemia, microalbuminuria non-alcoholic steatohepatitis (NASH) and increased CRP.
- Diagnosis is made, if any 3 out of the 5 criteria given above.

38. Which of the following is the basis for the intestine-specific expression of apoprotein B-48?

a) DNA rearrangement and loss

b) DNA rearrangement and loss

c) RNA alternative splicing

d) RNA editing

Correct Answer - D

Ans: D. RNA editing.

The production of apoB-48 in the intestine and apoB-100 in liver is the result of RNA editing in the intestine, where a sense codon is changed to a nonsense codon by post-transcriptional deamination of C to U. DNA rearrangement and transposition, as well as RNA interference and alternate splicing, do alter gene expression, but are not the basis of apoB-48 tissue-specific production.

Reference- Lippincott's Illustrated Reviews: Biochemistry, 5th edition, Regulation of Gene Expression, Pg 464.

39. A 30-year-old male came with complaints of swelling around the knee joint. Histopathological examination of the swelling demonstrated many giant cells interspersed with mononuclear cells. What is the probable diagnosis

a) Osteosarcoma

b) Ewing's sarcoma

c) Giant cell tumour

d) Chondrosarcoma

Correct Answer - C

Correct ans: C

GCTs are large and red-brown and often show cystic degeneration. They are composed of uniform oval mononuclear cells and scattered osteoclast-type giant cells containing 100 or more nuclei.

Mitotic figures are typically frequent.

Necrosis, hemorrhage, and reactive bone formation also are commonly present.

Ref Robbin's basics of pathology 9th edition page no.781

40. 30 years old came with complaints of easy fatigability, exertional dyspnea, and weight loss. She also complains of frequent falls. physical examination revealed there was a bilateral decrease in vibration sense. Her hemoglobin levels were 8.2g%. She was treated with folate. Her anemia improved but neurological symptoms worsened. Which of the following is the most probable reason for her condition?

a) Folate not absorbed

b) Unmasked pyridoxine deficiency

c) Deficiency of folate reductase in CNS

d) Folate therapy caused rapid use of Vit B12 stores aggravating symptoms

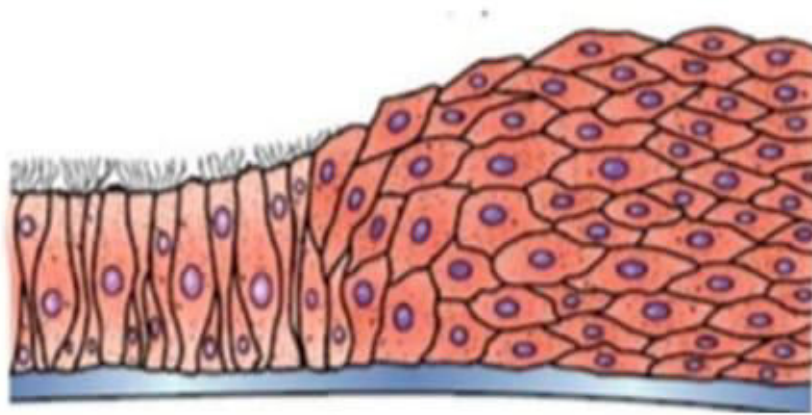
Correct Answer - D

Ans: D. Folate therapy caused rapid use of Vit B12 stores aggravating symptoms

Vitamin B12 is required for the recycling of tetrahydrofolate, the form of folate that is needed for DNA synthesis.

In keeping with this relationship, the anemia of vitamin B12 deficiency is reversed with the administration of folate. By contrast, folate administration does not prevent and may, in fact, worsen the

41. A 45-year-old man who is a chronic smoker came to the clinic with a complaint of cough. The physician examines the patient and takes a biopsy, the picture in the biopsy was as the description below. Which of the following cellular changes has happened to this patient?



a) Hyperplasia

b) Dysplasia

c) Metaplasia

d) CIN3

Correct Answer - B

Ans: C. Metaplasia

Metaplasia is a reversible change in which one adult cell type (epithelial or mesenchymal) is replaced by another adult cell type.

42. A 30-year-old woman presents with thyroid swelling. On investigations, her TSH levels are found to be elevated. Postoperative reports showed lymphocytic infiltration and hurthle cells. A most probable diagnosis is?

a) Graves disease

b) Hashimoto's thyroiditis

c) Follicular carcinoma

d) Medullary carcinoma thyroid

Correct Answer - B

Ans: B. Hashimoto's thyroiditis

Hashimoto thyroiditis is the most common cause of hypothyroidism which is characterized by gradual thyroid failure secondary to the autoimmune destruction of the thyroid gland.

It is most prevalent between the ages of 45 and 65 years and is more common in women than in men, ultimately leading to a varying degree of fibrosis and thyroid enlargement.

The thyroid usually is diffusely and symmetrically enlarged. The cut surface is pale and gray-tan in appearance, and the tissue is firm and somewhat friable.

Microscopic examination reveals the widespread infiltration of the parenchyma by a **mononuclear inflammatory infiltrate** containing small lymphocytes, plasma cells, and well-developed **germinal centers**.

The thyroid follicles are atrophic and are lined in many areas by

43. Which of the following will be seen on cardiac biopsy of a patient who had a post MI reperfusion injury?

a) Waviness of fibres

b) Eosinophilic contraction bands

c) Neutrophils in cardiac cells

d) Swelling of cells

Correct Answer - B

Ans: B. Eosinophilic contraction bands

Microscopically, irreversibly damaged myocytes subject to reperfusion show contraction band necrosis;

In this pathologic process, intense eosinophilic bands of hypercontracted sarcomeres are created by an influx of calcium across plasma membranes that enhances actin-myosin interactions.

44. Loss of foot process is classical in case of?

a) Membranous glomerulitis

b) Segmental glomerulosclerosis

c) IgA nephropathy

d) Diabetic nephropathy

Correct Answer - B

Ans: B. Segmental glomerulosclerosis

Focal segmental glomerulosclerosis (FSGS) is characterized by sclerosis, hyalinosis, adhesions/synechiae formation, resulting in segmental obliteration of glomerular capillaries. On EM, foot process effacement is the predominant finding without significant basement membrane abnormalities. Immunofluorescence shows staining for IgM and C3 in sclerotic areas. Juxtamedullary nephrons are affected first and hence inadequate sampling may miss focal lesions.

<https://www.ncbi.nlm.nih.gov/books/NBK532272/>

45. Which of the following factors play a major role in the initiation of thrombus formation?

a) Vasoconstriction

b) Coagulation cascade activation

c) Platelets activation

d) Endothelial injury

Correct Answer - D

Ans: D. Endothelial injury

The three primary abnormalities that lead to thrombus formation (called Virchow's triad) are

(1) endothelial injury,

(2) stasis or turbulent blood flow, and

(3) hypercoagulability of the blood.

Ref: robbins 9th edition chapter 4

46. A 33-year-old man presents with a 5-week history of calf pain, swelling, and low-grade fever. Serum levels of creatinine kinase are elevated. A muscle biopsy reveals numerous eosinophils also she had peripheral blood eosinophilia. Which of the following interleukins is primarily responsible for the increase in eosinophils in this patient?

a) IL 2

b) IL 4

c) IL 1

d) IL6

Correct Answer - B

Ans: B. IL 4

47. Which of the following is true about PAN?

- a) Microscopy shows fibrinoid necrosis in large arteries
- b) ANCA is positive
- c) 30% of people have HbsAg positive
- d) Patient have hypogammaglobulinemia

Correct Answer - C

Ans: C. 30% of people have HbsAg positive

Polyarteritis nodosa (PAN) is a necrotizing vasculitis involving small and medium-sized muscular arteries of multiple organs and tissues.

The disease occurs more commonly in adult males than females.

Most commonly affected organs, in descending order of frequency of involvement, are the kidneys, heart, gastrointestinal tract, kidneys, and muscle.

The condition results from immunologic response to an identifiable antigen that may be bacteria (e.g. streptococci, staphylococci, mycobacteria), viruses (e.g. hepatitis B virus, influenza virus, CMV), malarial parasite, certain drugs, and chemicals.

There is no association with ANCA,^[7] but about 30% of people with PAN have chronic hepatitis B and deposits containing HBsAg-HBsAb complexes in affected blood vessels, indicating an immune complex-mediated cause in that subset. Infection with the Hepatitis C virus and HIV are occasionally discovered in people affected by PAN.

Leukocytoclastic vasculitis, characterized by fibrinoid necrosis with neutrophilic infiltrate in the vessel wall. Many of the neutrophils are fragmented. This form is found in vasculitis caused by deposits of immune complexes.

48. A 23-year-old male presented with a history of fatigue and tiredness. On investigation, he was found to have Hb values of 9gm%, MCV of 101 FL. peripheral smear examination showed microcytic RBC and hypersegmented neutrophils. Which is most probable etiology

a) Lead poisoning

b) Iron deficiency anemia

c) Chronic alcoholism

d) Hemolytic anemia

Correct Answer - A

Ans: A. Lead poisoning

Findings

Microcytic Anemia - Iron Deficiency

Hypersegmented Neutrophils - B12 and Folic Acid Deficiency

Young & No H/o Of Alcohol Consumption [Patient came with a history of Fatigue and Tiredness] - Chronic Alcoholism can be ruled out

Hemolytic Anemia - may demonstrate red blood cell fragments called schistocytes, red blood cells that look like spheres (spherocytes), and/or red blood cells missing small pieces (bite cells). An increased number of newly made red blood cells (reticulocytes) may also be a sign of bone marrow compensation for anemia.

49. What is the main feature of chemotaxis as observed in white blood cells?

a) Increased random movement of neutrophils

b) Increased adhesiveness to intima

c) Increased phagocytosis

d) Unidirectional locomotion of neutrophils

Correct Answer - D

Ans: D. Unidirectional locomotion of neutrophils

Chemotaxis is defined as a unidirectional movement of leukocytes up to a concentration gradient of chemotactic molecules. All granulocytes, monocytes and to a lesser extent lymphocytes respond to chemotactic stimuli with varying rates of speed.

Chemoattractants are exogenous or endogenous. Exogenous agents are bacterial products. Endogenous mediators are:

- Components of complement pathway C5a
- Products of lipoxygenase pathway LTB₄
- Cytokines particularly those of chemokine families.

50. Which of the following anticancer drugs are competitive inhibitors of tyrosine kinase –

a) Imatinib and sunitinib

b) Letrozole

c) Bicalutamide

d) Fulvestrant

Correct Answer - A

Ans. is 'a' i.e., Imatinib and sunitinib

Molecular targeted agents

- Tyrosine kinase inhibitors
- Competitive inhibitors → Imatinib, Nilotinib, Sunitinib, Dasatinib, Erlotinib, Gefitinib, Lapatinib, Sorafenib (Remember all end with 'nib').
- Monoclonal antibodies → Cetuximab, panitumumab.
- HER₂/neu (ERB B₂) inhibitors Monoclonal antibody - Trastuzumab.
- Targeted antibody → Gemtuzumab (anti CD-33), Rituximab (anti - CD20), Alemtuzumab (anti CD-52).
- Vascular endothelial growth factor (VEGF) inhibitor → Monoclonal antibody - Bevacizumab.
- Proteasome inhibitors → Bortezomib.
- Histone deacetylase inhibitor → Vorinostat
- DNA - methyltransferase inhibitor → 5-azacytidine, 2-deoxy-5 azacytidine.
- All - trans-retinoic acid.
- Biological response modifier - Recombinant IL-2 (aldesleukin, denileukin).

51. Which is not a prokinetic agent?

a) Dopamine antagonist

b) 5HT₄ agonist

c) Macrolides

d) Diphenylmethane

Correct Answer - D

Ans: D. Diphenylmethane

Prokinetic drugs:

- These are drugs that promote gastrointestinal transit and speed gastric emptying by enhancing coordinated propulsive motility.
- This excludes traditional cholinomimetics and anti-ChEs which produce tonic and largely uncoordinated contraction.

Drugs included:

- Metoclopramide,
- Domperidone,
- Cisapride,
- Mosapride,
- Itopride

Ref: K. D. Tripathi 7th Edition. Page 663 - 665

52. Which of the following drugs act by inhibiting DNA replication?

a) 6 Mercaptopurine

b) Actinomycin D

c) Mitomycin C

d) Asparaginase

Correct Answer - A

Ans: A. 6 Mercaptopurine

6-Mercaptopurine acts by inhibiting DNA replication.

Antimetabolites:

- These are analogues related to the normal components of DNA or of coenzymes involved in the nucleic acid synthesis.
- They competitively inhibit the utilization of the normal substrate or get themselves incorporated forming dysfunctional macromolecules.

Includes:

- Folate antagonist - Methotrexate (Mtx)
- Purine antagonist - 6-Mercaptopurine (6-MP)
- Pyrimidine antagonist - 5-Fluorouracil (5-FU)

Purine antagonists

- Mercaptopurine (6-MP) and thioguanine (6-TG).
- These are highly effective antineoplastic drugs.
- After synthesis in the body to the corresponding mono ribonucleotides, they inhibit the conversion of inosine monophosphate to adenine and guanine nucleotides that are the building blocks for RNA and DNA.
- There is also feedback inhibition of de novo purine synthesis.
- They also get incorporated into RNA and DNA which are dysfunctional.

53. DOC for Onychomycosis?

a) Terbinafine

b) Fluconazole

c) Nystatin

d) Itraconazole

Correct Answer - A

Ans: A. Terbinafine

Onychomycosis (a fungal infection of the nail, usually caused by a dermatophyte).

Onychomycosis is more difficult to treat than most dermatophytosis because of the inherent slow growth of the nail.

Older antifungal agents (ketoconazole and griseofulvin) are unsuitable for onychomycosis because of their relatively poor efficacy and potential adverse effects.

Three recently developed antimycotic agents (fluconazole, itraconazole, and terbinafine) offer high cure rates and good safety profiles.

Ref: <https://www.ncbi.nlm.nih.gov/pmc/articles/PMC88888/>

54. Theophylline by what mechanism causes diuresis?

- a) PDE3 inhibition
- b) PDE4 inhibition
- c) Beta 2 agonist action
- d) Adenosine A1 receptor antagonism

Correct Answer - D

Ans: D. Adenosine A1 receptor antagonism

The mildly diuretic actions of both methylxanthines are mainly the result of inhibition of tubular fluid reabsorption along the renal proximal tubule.

Based upon the use of specific adenosine receptor antagonists and the observation of a complete loss of diuresis in mice with targeted deletion of the A1AR gene, transport inhibition by methylxanthines is mediated mainly by antagonism of adenosine A1 receptors (A1AR) in the proximal tubule.

Methylxanthines are weak renal vasodilators, and they act as competitive antagonists against adenosine-induced preglomerular vasoconstriction.

Caffeine and theophylline stimulate the secretion of renin by inhibition of adenosine receptors and removal of the general inhibitory brake function of endogenous adenosine.

Since enhanced intrarenal adenosine levels lead to reduced glomerular filtration rate in several pathological conditions theophylline has been tested for its therapeutic potential in the renal impairment following the administration of nephrotoxic substances such as radiocontrast media, cisplatin, calcineurin inhibitors or following ischemia-reperfusion injury.

55. Which of the following antimicrobials should not be given to a chronic asthmatic patient managed on theophylline therapy?

a) Erythromycin

b) Amoxicillin

c) Cefotaxime

d) Cotrimoxazole

Correct Answer - A

Ans: A. Erythromycin

Drugs which inhibit theophylline metabolism and increase its plasma level are Erythromycin, Ciprofloxacin, Cimetidine, Oral contraceptives, Allopurinol;

The dose should be reduced to 2/3.

Ref: K. D. Tripathi 7th Edition. Page. 226- 227

56. DOC of prophylaxis for motion sickness?

a) Promethazine

b) Prochlorperazine

c) Metoclopramide

d) Itopride

Correct Answer - A

Ans: A. Promethazine

Motion sickness:

- Antiemetics with the anticholinergic-antihistamine property are the first choice drugs for motion sickness.
- Antidopaminergic and anti-HT 3 drugs are less effective.
- All anti-motion sickness drugs act better when taken $\frac{1}{2}$ –1 hour before commencing the journey.
- Once sickness has started, it is more difficult to control; higher doses/parenteral administration may be needed.

Drugs Included:

- **Promethazine, diphenhydramine, dimenhydrinate:**
- These drugs afford protection of motion sickness for 4–6 hours.

Promethazine theoclate:

- This salt of promethazine has been specially promoted as an antiemetic, but the action does not appear to be significantly different from promethazine HCl.

57. Which of the following antihypertensive drug is avoided in patients with high serum uric acid levels?

a) Hydrochlorothiazide

b) Enalapril

c) Prazosin

d) Atenolol

Correct Answer - A

Ans: A. Hydrochlorothiazide

Long-term use of higher dose thiazides in hypertension has caused a rise in blood urate levels.

Ref: K. D. Tripathi 7th Edition. Page. 585

58. Mechanism of resistance to penicillins via beta-lactamase is

- a) Altered penicillin-binding proteins
- b) Drug efflux
- c) Breaks drug structure
- d) Alteration in 50S ribosome structure

Correct Answer - C

Ans: C. Breaks drug structure

β -lactamases are produced by staphylococci, Haemophilus, gonococci, etc. which inactivate penicillin G.

The β -lactamases may be present in low quantity but strategically located periplasmically (as in gram-negative bacteria) so that the drug is inactivated soon after entry, or maybe elaborated in large quantities (by gram-positive bacteria) to diffuse into the medium and destroy the drug before entry.

Beta-lactam antibiotics share the structural feature of a beta-lactam ring.

This feature is responsible for the inhibition of bacterial cell wall synthesis.

The target molecules are peptidoglycan cross-linking enzymes (e.g. transpeptidases and carboxypeptidases) which can bind beta-lactam antibiotics (penicillin-binding proteins, PBP).

Bacterial cell death is initiated by beta-lactam antibiotic-triggered release of autolytic enzymes.

In contrast to gram-positive bacteria (absence of an outer membrane), the antibiotic has to penetrate through porins of the outer membrane of gram-negative bacteria before touching PBP's. Bacterial resistance to beta-lactam antibiotics includes modification

59. A patient on lithium therapy developed hypertension. He was started on Thiazide for hypertension. After a few days, he developed coarse tremors and other symptoms suggestive of lithium toxicity. What is the probable mechanism of interaction?

a) Thiazide increases the tubular reabsorption of lithium

b) Thiazide inhibits the metabolism of lithium

c) Thiazides act as an add on the drug to lithium

d) All of the above

Correct Answer - A

Ans: A. Thiazide increases the tubular absorption of lithium

Drug Interaction:

- Diuretics + Lithium = Decreased excretion—rise in Li + level - toxicity;
- Diuretics (thiazide, furosemide) by causing Na + loss to promote proximal tubular reabsorption of Na + as well as Li + → plasma levels of lithium rise. Potassium-sparing diuretics cause milder Li + retention.
- Management: Reduce dose of lithium and monitor level.

Ref: K. D. Tripathi 7th Edition. Page. 449, 932

60. Which drug acts via the tyrosine kinase receptor?

a) Insulin

b) TSH

c) LH

d) MSH

Correct Answer - A

Ans: A. Insulin

Insulin acts on specific receptors located on the cell membrane of practically every cell, but their density depends on the cell type: liver and fat cells are very rich.

The insulin receptor is a receptor tyrosine kinase (RTK) which is a heterotetrameric glycoprotein consisting of 2 extracellular α and 2 transmembrane β subunits linked together by disulfide bonds.

Ref: K. D. Tripathi 7th Edition. Page. 261

61. Pegloticase is used for the treatment of an Ankylosing spondylosis

a) Reactive Arthritis

b) CPPD

c) Chronic tophaceous gout

d) Refractory Rheumatoid arthritis

Correct Answer - C

Ans: C. Chronic tophaceous gout

Pegloticase:

- Pegloticase is a medication for the treatment of the severe, treatment of refractory chronic gout.
- It is a third-line treatment in those in whom other treatments are not tolerated.

Ref Gout and other crystal arthropathies by Robert Terkeltaud]

62. Fluoroquinolone contraindicated in liver disease is

a) Levofloxacin

b) Pefloxacin

c) Ofloxacin

d) Lomefloxacin

Correct Answer - B

Ans: B. Pefloxacin

Pefloxacin has longer $t_{1/2}$: accumulates on repeated dosing achieving plasma concentrations twice as high as after a single dose.

Because of this, it is effective in many systemic infections as well.

The dose of pefloxacin needs to be reduced in liver disease, but not in renal insufficiency.

Ref: K. D. Tripathi 7th Edition. Page. 713

63. At a high altitude of 3000 m, a person complains of breathlessness. All of the following can be used for the management of this person except?

a) Intravenous digoxin

b) Oxygen supplementation

c) Immediate descent

d) Acetazolamide

Correct Answer - A

Ans: A. Intravenous digoxin

Management of AMS follows three axioms: a) further ascent should be avoided until the symptoms have resolved, b) patients with no response to medical treatment should descend to a lower altitude and c) if and when HACO is suspected, patients should urgently descend to a lower altitude.

Descent and supplementary oxygen are the treatments of choice and for severe illness, the combination provides optimal therapy. Remarkably, a descent of only 500 to 1000 m usually leads to resolution of acute mountain sickness while high-altitude cerebral edema(HACO) may require further descent. Simulated descent with portable hyperbaric chambers, now commonly available in remote locations, are also effective.

Medical therapy becomes crucial when the descent is not immediately possible.

Ref: <https://www.ncbi.nlm.nih.gov/pmc/articles/PMC4923381/#!po>

64. A patient with diabetes and COPD developed postoperative urinary retention. Which of the following drugs can be used for short term treatment to relieve the symptoms of this person?

a) Bethanechol

b) Methacholine

c) Terazosin

d) Tamsulosin

Correct Answer - A

Ans: A. Bethanechol

Bethanechol is a preferred drug in the treatment of postpartum and **postoperative** nonobstructive **urinary retention**, and it also can counteract **bladder** dysfunction often seen with phenothiazines and tricyclic antidepressants.

It can afford symptomatic relief in congenital megacolon and gastroesophageal reflux but is rarely used for these.

Ref: <https://www.pdr.net/drug-summary/Urecholine-bethanechol-chloride-801>,

K. D. Tripathi 7th Edition. Page. 104

65. Drug of choice for invasive aspergillosis is

a) Posaconazole

b) Voriconazole

c) Liposomal AMB

d) Caspofungin

Correct Answer - B

Ans: B. Voriconazole

The preferred treatment of primary IA is voriconazole, which has been found to be superior to amphotericin B.

Azoles interfere with the synthesis of ergosterol found in the fungal cell membrane, whereas polyenes -- such as amphotericin B -- interfere with ergosterol function.

An echinocandin that disrupts fungal cell wall synthesis -- caspofungin -- and itraconazole have been approved for salvage therapy of IA.

Ref: <https://www.ncbi.nlm.nih.gov/pmc/articles/PMC4200583/>

66. Which of the following drugs acts by inhibiting the transcription of DNA to RNA?

a) Rifampicin

b) Nitrofurantoin

c) Ciprofloxacin

d) Novobiocin

Correct Answer - A

Ans: A. Rifampicin

Overall **inhibition** of **RNA** synthesis by **rifampicin** is caused by a destabilizing effect on the binding of the intermediate oligonucleotides to the active enzyme-**DNA** complex.

Rifampicin itself can only interact specifically with **RNA** polymerase if the enzyme is free or in a binary complex with **DNA**.

Ref: <https://www.ncbi.nlm.nih.gov/pmc/articles/PMC327649/>

67. A patient was recently started on Fluphenazine. A few weeks later, he developed tremors, rigidity, bradykinesia, and excessive salivation. The first line of management for this patient is

a) Selegiline

b) Trihexyphenidyl

c) Pramipexole

d) Amantadine

Correct Answer - B

Ans: B. Trihexyphenidyl

* Fluphenazine may block the effects of agents used to treat Parkinson's disease such as levodopa/carbidopa.

* **Trihexyphenidyl** is an antispasmodic drug that exerts a direct inhibitory effect on the parasympathetic nervous system.

- It also has a relaxing effect on smooth muscle.

- It is indicated in all forms of Parkinsonism.

* Trihexyphenidyl works as an anticholinergic and is used for the treatment of tremors, spasms, stiffness, and weak muscle control seen in patients with Parkinson's disease.

- It can also be used for the prevention or treatment of similar muscular conditions which are caused by certain central nervous system (CNS) drugs such as fluphenazine, haloperidol, chlorpromazine.

Ref: <https://www.ncbi.nlm.nih.gov/books/NBK519488/>, <https://www.ncbi.nlm.nih.gov/pmc/articles/PMC519488/>

68. A person was given a muscle relaxant that competitively blocks nicotinic receptors. Which of the following drugs is used for reversal of muscle relaxation after surgery?

a) Neostigmine

b) Carbachol

c) Succinylcholine

d) Physostigmine

Correct Answer - A

Ans: A. Neostigmine

Neostigmine has been traditionally used as the agent of choice to **reverse** Neuromuscular Blockade (NMB) **after muscle** paralysis during general anesthesia.

Anticholinesterases (neostigmine) are generally used to reverse the effects of neuromuscular blocking agents.

Ref: <https://www.hindawi.com/journals/cria/2017/8197035/>

69. Zero-order kinetics is otherwise known as saturation kinetics. It is independent of:

a) Plasma concentration

b) Clearance

c) Volume of distribution

d) Half life

Correct Answer - A

Ans. A. Plasma concentration

- In zero-order kinetics or saturation kinetics, elimination mechanisms become saturated and unable to process more drugs when drug concentrations rise.
- Consequently, ***for drugs that are eliminated by zero-order kinetics, a constant amount of drug is eliminated per unit time regardless of drug plasma concentration.***

70. Which of the following anticancer drugs are competitive inhibitors of tyrosine kinase –

a) Imatinib and sunitinib

b) Letrozole

c) Bicalutamide

d) Fulvestrant

Correct Answer - A

Ans. is 'a' i.e., Imatinib and sunitinib

Molecular targeted agents

Tyrosine kinase inhibitors

Competitive inhibitors → Imatinib, Nilotinib, Sunitinib, Dasatinib, Erlotinib, Gefitinib, Lapatinib, Sorafenib (Remember all end with 'nib').

Monoclonal antibodies → Cetuximab, panitumumab.

HER₂/neu (ERB B₂) inhibitors Monoclonal antibody - Trastuzumab.

Targeted antibody → Gemtuzumab (anti CD-33), Rituximab (anti - CD20), Alemtuzumab (anti CD-52).

Vascular endothelial growth factor (VEGF) inhibitor → Monoclonal antibody - Bevacizumab.

Proteasome inhibitors → Bortezomib.

Histone deacetylase inhibitor → Vorinostat

DNA - methyltransferase inhibitor → 5-azacytidine, 2-deoxy-5 azacytidine

All - trans-retinoic acid.

Biological response modifier - Recombinant IL-2 (aldesleukin, denileukin)

71. Which of the following is the law on child sexual abuse in India?

a) Child Sexual Abuse Prevention Act

b) Protection Of Children from Sexual Offences Act (POCSO)

c) Child Welfare Act

d) Sexual Offences Act

Correct Answer - B

Ans: B. POSCO Act

The Protection of Children from Sexual Offences (POSCO) Act, 2012,2019

- It is applicable to the whole of India.
- It defines a child as any person below the age of 18 years and provides protection to all children
- Offences covered under the Act:
- Penetrative Sexual Assault
- Aggravated Penetrative Sexual Assault
- Sexual Assault
- Aggravated Sexual Assault
- Sexual Harassment of the Child
- Use of Child for Pornographic Purposes

72. Punishment of perjury comes under IPC section?

a) IPC 191

b) IPC 192

c) IPC 193

d) IPC 197

Correct Answer - C

Ans: C. IPC 193

Defines punishment for fabricating false evidence

The witness is liable to be prosecuted for perjury, and the imprisonment may extend up to seven years.

193 IPC: punishment for false evidence, (punishment for perjury): imprisonment up to 7 years and also liable for fine

191 IPC: Giving false evidence (perjury) under oath.

192 IPC: Fabricating false evidence (perjury)

THE ESSENTIALS OF FORENSIC MEDICINE AND TOXICOLOGY

-Dr. K.S. NARAYAN REDDY 33rd edition-pg-13

73. When civil negligence is brought up against a doctor, the onus of proof lies upon -

- a) Judicial first-degree magistrate
- b) Police not below the level of sub-inspector
- c) Doctor
- d) Patient

Correct Answer - D

Ans: D. Patient

"Generally speaking, it is for the patient in an action for negligence to establish the guilt of the doctor, whose innocence is otherwise assumed."- Parikh

However, in cases where the rule of res ipsa loquitur is applied, the patient need not prove negligence. Res ipso loquitur means that "the thing or fact speaks for itself." The patient has to merely state what according to him was the act of negligence.

Civil negligence

- When a patient (or his relative, in case of patient's death) files suit in a civil court to get compensation from his doctor for the injury or death of the patient due to doctor's negligence.
- A doctor files a civil suit to get fees from his patient, who refuses to pay alleging negligence.

Note that?

- Even if a doctor is negligent, a patient is not entitled to any compensation if no damage has occurred.
- An error in diagnosis or treatment is not negligence provided proper care and skill has been exercised.

•

•

74. Relatives of a patient told during postmortem examination that the person had a tattoo - which was now invisible. How to identify?

a) Examine the Lymph node

b) Spectrophotometer

c) Ordinary light

d) X-ray

Correct Answer - A

Answer- A-Examine the Lymph node

Tattoo marks are permanent when dye penetrates the dermis.

Infrared photography makes old tattoos readily visible.

A faded tattoo mark becomes visible by the use of ultraviolet lamp or rubbing the part and examining with a magnifying lens.

Marks are recognized even in decomposed bodies(Aret) when the epidermis is removed. Lymph nodes near the tattoo mark show pigment deposition.

75. True about hymen in Child rape is-

- a) Hymen easily tears because it is thin
- b) Hymen easily tears because it is in the front
- c) Hymen hardly tears because it is highly elastic
- d) Hymen hardly tears because it is situated deep

Correct Answer - D

Answer-D- Hymen hardly tears because it is situated deep

The hymen may not rupture after rape if:

- Penetration was not full
- The hymen is tough, fleshy and elastic
- In a young child, full penetration may not occur

Gautam Biswas Review of forensic medicine & Toxicology 2/e; pg-332

https://www.who.int/violence_injury_prevention/resources/publications/

76. Magnan's symptoms are related to

a) Cocaine poisoning

b) Cannabis

c) Cannabis

d) Alcohol

Correct Answer - A

Answer:A. Cocaine poisoning

Magnan's sign or Symptom is a clinical sign in which people with **cocaine** addiction experience **paraesthesia** which feels like a constantly moving foreign bodies, (**cocaine** bugs) such as fine sand or powder, under the **skin**. It is the most tactile hallucination.

Degeneration of the central nervous system occurs, and the patient may suffer from hallucinations, convulsions, delirium, and insanity.

Magnan's symptom or cocaine bugs is characteristic, in which there is a feeling as if grains of sand are lying under the skin or some small insects are creeping on the skin giving rise to itching sensation (formication, tactile hallucination) with resultant excoriation, leading to irregular scratches and ulcers.

THE ESSENTIALS OF FORENSIC MEDICINE AND TOXICOLOGY
By Dr. K.S. NARAYAN REDDY 33/e- pg-603

77. Parents of the Child complains of assaulted by one of their relatives and anal pain in a child, On investigation test shows yellow iodine crystals with picric acid - what is the name of the test?

a) Florence test

b) Barberio's test

c) Acid phosphatase test

d) Creatine Phosphokinase

Correct Answer - B

Answer: B. Barberio's test

It detects spermin (secreted by the prostate) and uses an aqueous or alcoholic solution of picric acid.

A saturated aqueous or alcoholic solution of picric acid, when added to the spermatic fluid, produces yellow needle-shaped rhombic crystals of spermine picrate. The reaction probably depends on the presence of prostatic secretion.

The Acid Phosphatase Test: The prostatic secretion element of seminal fluid contains 500 to 1000 times greater acid phosphatase than any other body fluid. Human red cells, semen of higher apes, and juice of cauliflower have acid phosphatase level similar to that of human semen

THE ESSENTIALS OF FORENSIC MEDICINE AND TOXICOLOGY
By Dr. K.S. NARAYAN REDDY 33/e- pg-434

78. The Magistrate can detain the maximum number of days for a mentally ill person as per mental health care is

a) 30 days

b) 90 days

c) 50 days

d) 100 days

Correct Answer - A

Ans: A. 30 days

* If the Magistrate is satisfied that it is necessary to detain the alleged mentally ill person in a psychiatric hospital, he passes a Reception Order (order for admission and detention), which is valid for 30 days. If he is not satisfied, he may refuse the application, giving his reasons in writing, a copy of which is supplied to the applicant.

* Admission Under Special Circumstance

- A mentally ill person may not be able to express his willingness for admission as a voluntary patient, Such person can be admitted in a psychiatric hospital (psychiatric nursing home) for a period of 90 days if an application is made by a relatives and friends

79. Vector for zika virus is -

a) Aedes

b) Culex

c) Anopheles

d) None of these

Correct Answer - A

Ans: A. Aedes

Zika virus disease is caused by the **Zika virus**, which is **spread** to people primarily through the bite of an infected mosquito (*Aedes aegypti* and *Aedes albopictus*). The **virus** can also be **transmitted** through sex.

These are the same mosquitoes that spread dengue and chikungunya viruses.

A mosquito gets infected with a virus when it bites an infected person during the period of time when the virus can be found in the person's blood, typically only through the first week of infection.

Medical Microbiology and Immunology 14/e-pg;395

80. All are true regarding Japanese encephalitis except ?

- a) Caused by flavivirus
- b) Humans are dead-end hosts
- c) Transmitted by culex
- d) Cattles are amplifier hosts

Correct Answer - D

Ans. is 'd' i.e., Cattles are amplifier hosts

Japanese encephalitis

- Caused by a group *B arbovirus (flavivirus)*
- It is a *Zoonotic disease* ie infecting mainly animals and incidentally man.
- In south, epidemics have occurred in *Karnataka*, Andhra Pradesh, TamilNadu, and Kerala.
- Human, cattle, and horses are dead-end hosts as the disease manifests as fatal encephalitis.
- Pigs act as an amplifying host and have a very important role in the epidemiology of the disease.
- Infection in swine is asymptomatic, except in pregnant sows, when abortion and fetal abnormalities are common sequelae.
- The most important vector is *Culex tritaeniorhynchus*, which feeds on cattle in preference to humans.
- The natural hosts of the Japanese encephalitis virus are birds, not humans.
- In November 2011, the Japanese encephalitis virus was reported in *Culex bitaeniorhynchus* in South Korea

81. All of the following is/are having superantigen Property Except

- a) Vibrio cholera
- b) Streptococcal pyrogenic
- c) Staphylococcal enterotoxins
- d) None of these

Correct Answer - A

Answer-A- Vibrio Cholera

SAgs are produced by some pathogenic viruses and bacteria most likely as a defense mechanism against the immune system.

Toxic shock syndrome toxin (TSST-1), epidermolytic toxin and other staphylococcal enterotoxin are superantigens.

These superantigens can bind MHC molecules outside the peptide-binding cleft.

Consequently, superantigen can activate up to 10% of T-cells in a nonspecific manner which in turn leads to the release of large quantities of cytokines.

Jawetz 27/e-pg-135

82. Type A bioterrorism Agent-

a) Chikungunya

b) Anthrax

c) Hendra

d) Influenza

Category A	Category B	Category C
Anthrax	Caliciviruses	Antimicrobial Resistance
Botulism	Chikungunya	Hendra
Dengue	Cholera	Influenza (highly pathogenic strains)
Ebola	E. coli O157: H7	MERS
Hantavirus	Hepatitis A	Nipah
Lassa	Ricin toxin	Prions
Marburg	Salmonella	Rabies
Plague	Typhus fever	SARS
Smallpox	Yellow fever	Tick-Borne encephalitis
Tularemia	Zika	Tuberculosis

83. Culture media used for *E.coli* 0157:H7 is

- a) SMAC
- b) Wilson and Blair medium
- c) Potassium tellurite in Mcleod's medium
- d) Deoxycholate citrate agar (DCA)

Correct Answer - A

Answer- A- SMAC

An enterohemorrhagic bacterial strain, *E. coli* O157: H7 infects the alimentary tract and induces abdominal cramps with hemorrhagic diarrhea. Transmission of *E. coli* O157: H7 occurs via the fecal-oral route after consumption of contaminated, undercooked liquids and foods.

Mac Conkey-Sorbitol ChromoSelect Agar (SMAC) is recommended for selective isolation of *Escherichia coli* 0157:H7 from food and animal feeding stuffs.

MacConkey Sorbitol Agar is based on the formulation described by Rappaport and Henigh. The medium contains sorbitol instead of lactose and it is recommended for the detection of enteropathogenic strains of *E. coli* 0157:H7 which ferments lactose but does not ferment sorbitol and hence produce colorless colonies.

Sorbitol fermenting strains of *E. coli* produce pink-red colonies. The red color is due to the production of acid from sorbitol, absorption of neutral red and a subsequent colour change of the dye when the pH of the medium falls below 6.8.

<https://www.sigmaaldrich.com/analytical-chromatography/microbiology/microbiology-products.html?TablePage=18297647>

84. Donovanosis is Caused By-

a) *H. ducreyi*

b) *Leishmania donovani*

c) *K. granulomatis*

d) *Treponema pallidum*

Correct Answer - C

Answer- C- K. Granulomatis

- **Donovanosis is a sexually transmitted genital ulcer disease.**
- **The bacterium that causes donovanosis (*Klebsiella granulomatis*) infects the skin around the genitals, groin or anal area and causes ulcers and destruction of the skin.**

85. Fungal Infection which is acquired by traumatic inoculation is?

- a) Sporothrix
- b) Blastomycosis
- c) Coccidioides
- d) Paracoccidioides

Correct Answer - A

Answer-A- Sporothrix

Sporothrix schenckii is a thermally dimorphic fungus that lives on vegetation. It is associated with a variety of plants, grasses, trees, sphagnum moss, rose bushes, and other horticultural plants.

The conidia or hyphal fragments of S.schenckii are introduced into the skin by trauma.

Following a traumatic introduction into the skin, S.schenckii causes sporotrichosis, a chronic granulomatous infection.

This manifestation mimics chronic cavitary tuberculosis and tends to occur in patients with impaired cell-mediated immunity.

Jawetz 27/e-pg-670

86. Which of the following is not involved in urethritis

a) Trichomonas

b) H.ducreyi

c) Chlamydia

d) Gonococcus

Correct Answer - B

Answer-B- H.ducreyi

Bacteria that commonly cause urethritis to include:

- E. coli and other bacteria present in the stool
 - Gonococcus, which is sexually transmitted and causes [gonorrhea](#).
 - Chlamydia trachomatis, which is sexually transmitted and causes [chlamydia](#).
 - The [herpes simplex](#) virus (HSV-1 and HSV-2) can also cause urethritis. Trichomonas is another cause of urethritis
- [-https://www.webmd.com/a-to-z-guides/urethritis-symptoms-causes-treatments#1](https://www.webmd.com/a-to-z-guides/urethritis-symptoms-causes-treatments#1) ; Jawetz 27/e-pg-746

87. A patient complains about nausea, vomiting and stomach cramps after attending a social gathering party, which causative organism is likely responsible for Food Poisoning within 3 hours.

a) Staphylococcus aureus

b) Salmonella

c) Clostridium botulinum

d) Clostridium perfringens

Correct Answer - A

Answer- A- Staphylococcus aureus

Staph food poisoning is characterized by a sudden start of nausea, vomiting, and stomach cramps. Most people also have diarrhea. Symptoms usually develop within 30 minutes to 6 hours after eating or drinking an item containing Staph toxin and last no longer than 1 day. Severe illness is rare.

The illness cannot be passed from one person to another.

<https://www.cdc.gov/foodsafety/diseases/staphylococcal.html>

88. A 46-year-old woman with HIV *complains* severe persistent diarrhea, Histological Investigation was performed, Identify the organism causing diarrhea in HIV Patient.

a) Cryptosporidium

b) Staphylococcus aureus

c) Salmonella

d) Clostridium botulinum

Correct Answer - A

Answer-A- Cryptosporidium

* The origin of infectious diarrhea in patients with AIDS can be divided into 2 general categories: that caused by common pathogens and that caused by opportunistic pathogens.

* The most common infectious organisms causing AIDS-related diarrhea include

- Cytomegalovirus (CMV)
- The parasites Cryptosporidium,
- Microsporidia
- Giardia lamblia

* And the bacterium Mycobacterium avium-intracellulare (MAC).

* Other bacteria and parasites that cause diarrheal symptoms in otherwise healthy people may cause more severe, prolonged or recurrent diarrhea in people with HIV or AIDS.

<https://aidsinfo.nih.gov/news/175/aids-related-diarrhea>

89. Organism Causing LGV

a) *Chlamydia trachomatis*

b) *Neisseria gonorrhoeae*

c) *Treponema pallidum*

d) *Haemophilus ducreyi*

Correct Answer - A

Answer- A- *Chlamydia trachomatis*

Lymphogranuloma venereum (LGV) is a long-term (chronic) infection of the lymphatic system.

It is caused by any of the 3 different types (serovars) of the bacteria *Chlamydia trachomatis*.

The bacteria are spread by sexual contact. The infection is not caused by the same bacteria that cause genital [chlamydia](#).

Chlamydia trachomatis causes eye (conjunctivitis, trachoma), respiratory (pneumonia), and genital tract (urethritis, lymphogranuloma venereum) infections.

Diagnosis made with the nucleic acid test for *C.trachomatis*, LGV serovars diagnosed serologically.

Lange Review of Medical Microbiology & Immunology 14/e 208

90. Which interleukin responsible for producing IgE from B cells

a) IL 1

b) IL 3

c) IL 4

d) Both B & C

Correct Answer - C

Answer- C, IL 4

IgE is produced by plasma cells located in lymph nodes draining the site of [antigen](#) entry or locally, at the sites of allergic reactions, by plasma cells derived from germinal centers developing within the inflamed tissue.

IgE [antibody](#) production requires [TH2 cells](#) that produce interleukin-4 ([IL-4](#)) and IL-13 and it can be inhibited by [TH1 cells](#) that produce interferon- γ ([IFN- \$\gamma\$](#)).

<https://www.ncbi.nlm.nih.gov/books/NBK27117/>

91. HbsAg is based on which principle

a) Immunochromatography assays

b) Chemiluminescence

c) ELISA

d) Immunofluorescence

Correct Answer - A

Answer- A- Immunochromatography assays

HBV chronic carriers are those in whom HBsAg persists for more than 6 months in the presence of HBeAg or anti-HBe. HBsAg may persist for years after the loss of HBeAg. The most useful detection methods are enzyme-linked Immunosorbent assay for HBV antigens and antibodies and PCR for viral DNA -**Jawetz 27/e pg-504**

Serological assays detect the host immune response (antibodies to HCV) or a viral antigen (HBsAg, HCVcAg). They are based on the immunoassay principle and are available in the form of rapid diagnostic tests (RDTs) or laboratory-based enzyme immunoassays (EIAs), chemiluminescence immunoassays (CLIAs) and electrochemiluminescence immunoassays (ECLs).-

<https://www.ncbi.nlm.nih.gov/books/NBK442281/>

92. Nosocomial Infection occurs within?

a) A- 48

b) B. 72

c) C. 24

d) D. 50

Correct Answer - A

Answer- A- 48 hours

A hospital-acquired infection (HAI), also known as a nosocomial infection, is an infection that is acquired in a hospital or other health care facility.

Nosocomial infections can be defined as those occurring within 48 hours of hospital admission or within 3 days of discharge or 30 days of operation.

Some well known nosocomial infections include:

- ventilator-associated pneumonia,
- Methicillin-resistant *Staphylococcus aureus*,
- *Candida albicans*,
- *Acinetobacter baumannii*,
- *Clostridium difficile*,
- Tuberculosis,
- Urinary tract infection, Vancomycin-resistant *Enterococcus*, and Legionnaires' disease.

<https://www.ncbi.nlm.nih.gov/books/NBK441857/>

93. Which of the following cell components produced by *Neisseria gonorrhoeae* is responsible for attachment to host cells?

a) Lipooligosaccharide

b) Pili (fimbriae)

c) IgA1 protease

d) Outer membrane porin protein

Correct Answer - B

Answer- B- Pili (fimbriae)

Pili are hair-like appendages that extend up to several micrometers from the gonococcal surface. They enhance attachment to host cells and resistance to phagocytosis. They are made up of stacked pilin proteins.

The amino terminal of the pilin molecule, which contains a high percentage of hydrophobic amino acids, is conserved. The amino acid sequence near the midportion of the molecule also is conserved; this portion of the molecule serves in an attachment to host cells and is less prominent in the immune response.

The amino acid sequence near the carboxyl-terminal is highly variable; this portion of the molecule is most prominent in the immune response. The pilins of almost all strains of *N. gonorrhea* are antigenically different, and a single strain can make many antigenically distinct forms of pilin

Jawetz 27/e-pg-282

94. Where will you put chemical liquid biomedical waste

a) White

b) Yellow

c) Blue

d) Red

Correct Answer - B

Ans. B yellow

Chemical waste is categorized into the yellow category. the hazardous chemical and cytotoxic waste is a yellow category with a special sign of "CYTOTOXIC" waste.

Another liquid waste as body secretions is categorized into the yellow category of biomedical waste guidelines, 2016

Park's PSM 24th ed. Page no. 831

95. Maximum work hours for a person including overtime under the factories act:

a) 48

b) 50

c) 60

d) 100

Correct Answer - C

Ans: C. 60 hours.

Factories act permits work for 48 hours per week with 2 hours of overtime every day.

making it approximately 60 hours of maximum work as per the factories act of India

Park's PSM 24th ed. Page no. 852

96. The vaccine to be given after disaster

- a) vaccination against typhoid
- b) vaccination against cholera
- c) vaccination against typhoid and cholera
- d) vaccination against tetanus

Correct Answer - D

Ans. D. vaccination against tetanus.

The major concern for anyone exposed to unsanitary conditions is that they should be up to date with the tetanus-containing vaccine because if they are injured (as is common in disaster settings) the injury is likely to be contaminated.

Routinely recommended vaccines are recommended for evacuees, just like they are for everyone else.

Cholera and typhoid vaccine do not have any evidence for mass vaccination due to the low level of exposure and prevention

Tetanus and HepB vaccine is required.

97. What is the MONICA project?

- a) Multinational monitoring of trends and determinants in Cardiovascular Disease
- b) Multinational of trends and determinants in cerebrovascular disease
- c) Multinational monitoring of trends and determinants in diabetes
- d) Multinational monitoring of trends and determinants in congenital heart disease

Correct Answer - A

Ans: A. Multinational monitoring of trends and determinants in Cardiovascular Disease

The WHO has completed a project known as MONICA " (multinational monitoring of trends and determinants in cardiovascular diseases)" to elucidate this issue.

Forty-one centers in 26 countries were participating in this project, which was planned to continue for a 10 year period ending in 1994.

Park's PSM 24th ed. Page no. 385

98. Extended sickness benefit for tuberculosis under the ESI Act is:

a) 91 days

b) 1-year

c) 2 years

d) 4 years

Correct Answer - C

Ans. C. 2 years

EXTENDED SICKNESS BENEFIT: In addition to 91 days of sickness benefit insured persons suffering from certain long-term diseases are entitled to Extended Sickness Benefit as shown below, for a maximum period of two years.

Extended Sickness Benefit with effect from 1.1.2000 is payable, in the case where the insured person has been in continuous employment for 2 years Tuberculosis

Park's PSM 24th ed. Page no. 854

99. A person reports 4 hours after having a clean wound without laceration. He had taken TT 10 years before. the next step in management is:

a) Full course Tetanus vaccine to be given

b) Full dose TT with TIG

c) Single-dose TT

d) No need for any vaccine

Correct Answer - C

Ans. C. Single-dose TT

A patient with wound less than 6 hours old if clean, non-penetrating and with negligible tissue damage if had a complete course of toxoid or a booster dose more than 10 years ago(category C) should be treated with Toxoid 1 dose.

Park's PSM 24th ed. Page no. 331

100. Recent Influenza Pandemic was due to:

a) H1N1

b) H5N1

c) H7N7

d) H3N2

Correct Answer - A

Ans. A. H1N1

H1N1 – swine flu – cause the major flu Pandemic (1918 and 2009)

H5N1 – avian influenza. may cause sporadic outbreaks or epidemics. It is associated with high mortality.

101. Mission Indradhanush is for:

a) Non-communicable diseases

b) Universal immunization

c) Family planning

d) Safe water and sanitation

Correct Answer - B

Ans. B. Universal immunization

The Ministry of Health & Family Welfare has launched " Mission Indra Dhanush", depicting seven colours of the rainbow in December 2014, to fully immunize more than 89 lakh children who are either unvaccinated or partially vaccinated; those that have not been covered during the rounds of routine immunization for various reasons.

They will be fully immunized against seven life-threatening vaccine-preventable diseases which include diphtheria, whooping cough, tetanus, polio, tuberculosis, measles, and hepatitis-B.

In addition, vaccination against Japanese Encephalitis and Haemophilus influenza type B will be provided in selected districts/states of the country.

Pregnant women will also be immunized against tetanus.

Ref. Park's PSM 24th ed. Page 462

102. A study had a normal distribution with the median value as 200 and standard deviation 20. 68 % will fall between

a) 160-240

b) 170-230

c) 180-220

d) 190-210

Correct Answer - C

Ans. C. 180-220

As the median value is 200 and the standard deviation is 20, the normal distribution is:

68% of the population will have values between – median \pm 1 SD = $220 \pm 20 = 180-220$

95% of the population will have values between – median \pm 2 SD = $220 \pm 40 = 160-240$

Note: in the MCQ, as the data shows a normal distribution, the median will be equal to mean and the mode.

Park's PSM Ed. 24th page no. 885

103. Which of the following is a technique/method based on behavioural sciences

a) Management by objectives

b) Network analysis

c) Systems analysis

d) Decision making

Correct Answer - A

Ans. A. Management by objectives

The methods based on behavioural sciences include

- organizational design
- personal management
- Management by objectives
- information systems
- communication

The Quantitative methods include:

- cost-benefit analysis
- cost-effective analysis
- input-output analysis
- network analysis as PERT and CPM
- Planning programming budgeting systems
- decision making

Ref: Park's 25ed, Page no. 934

104. As per the sustainable development goals, The target for MMR is to achieve maternal deaths of

a) < 70 / Lac live births

b) < 100 / lac live births

c) < 7 / 1000 live births

d) < 10 / 1000 live births

Correct Answer - A

Ans: A. < 70 / Lac live births

By 2030, reduce the global maternal mortality ratio to less than 70 per 100,000 live births.

Park's PSM 24th ed. Page no. 28 Table: 4

105. The best method for routine monitoring of air pollution

- a) Sulphur dioxide, smoke, and particulate matter
- b) Sulphur dioxide, Hydrogen sulphide, carbon monoxide
- c) Carbon dioxide, hydrogen sulphide, lead
- d) Sulphur dioxide, Lead and particulate matter

Correct Answer - D

Ans. D Sulphur dioxide, Lead and particulate matter

Air quality index consists of:

- Particulate matter (less than 2.5 micrometers and 10 micrometer – PM2.5 and PM10)
- Nitrogen dioxide (NO₂)
- Sulphur dioxide (SO₂)
- Carbon monoxide (CO)
- Ozone (O₃)
- Ammonia (NH₃)
- Lead (Pb)

Reference: <https://pib.gov.in/newsite/PrintRelease.aspx?relid=110654>

106. The variation in data is compared with another data set by:

a) Variance

b) Coefficient of variation

c) The standard error of mean

d) Standard deviation

Correct Answer - B

Ans. B. Coefficient of variation

Variance: Is the square of SD which tells about the standard deviation

Coefficient of variation: It may help by comparing the variations in the data set

The standard error of the mean: It is to compare the means of the data sets which have a different sample size, central tendency, and standard deviations

Standard deviation: It is the deviation of values from the mean

Ref. Fundamentals of Biostatistics - 7th Edition (Pg 20, 21)

107. In which of the following methods of management is the benefit measured in natural units?

a) Program budgeting system

b) Network analysis

c) Cost-effective analysis

d) Cost-benefit analysis

Correct Answer - C

Ans. C. Cost-effective Analysis

In cost-effective analysis (CEA), benefits are measured in natural units of the outcomes of the programs (life-years gained, cases prevented, etc.) and the costs are measured in monetary units.

The most comprehensive indicator of CEA is Quality-Adjusted Life Years (QALYs).

Park's PSM 24th ed. Page no. 908

108. The difference between the incidence in the exposed and non-exposed group is best given by:

a) Relative risk

b) Attributable risk

c) Population attributable risk

d) Odds ratio

Correct Answer - B

Ans. B Attributable Risk

Attributable Risk

Attributable Risk is the difference in incidence rates or proportions of disease or death between an exposed and non-exposed group.

$$\text{Attributable risk (AR)} = \frac{\text{Incidence of disease rate among exposed} - \text{Incidence of disease rate among non-exposed}}{\text{Incidence of disease rate among exposed}} \times 100$$

It is expressed in percentage and gives the extent to which the disease can be attributed to the exposure in a cohort study.

Reference: Park 25th Edition, page no:86

109. If one variable is given then you can find another variable by

a) Coefficient of variation

b) Coefficient of correlation

c) Coefficient of regression

d) Coefficient of determination

Correct Answer - C

Ans. C. Coefficient of regression

The coefficient of correlation tells about the strength of association but not about quantity. On the other hand, the coefficient of regression is used for quantification.

If we wish to know in an individual case the value of one variable, knowing the value of the other, we calculate what is known as the regression coefficient of one measurement to the other. It is customary to denote the independent variable by x and the dependent variable by y .

110. Prospective screening is done in case of?

- a) Neonate for thyroid diseases
- b) Immigrant screening
- c) Pap smear for 45-year female
- d) Diabetes mellitus for 40-year male

Correct Answer - B

Ans. B. Immigrant Screening

Screening of immigrants to a country is an example of prospective screening.

Prospective screening:

- People screened for others benefit
- The essential purpose is case detection
- Requested for screening for disease control; specific request from the authority

111. A researcher wanted to prove the relation between COPD and smoking. He collected patients records from government hospitals and records of cigarette sales from the finance and taxation department. This is an example of which study design:

a) Cross-sectional

b) Posological study

c) Ecological study

d) Operations research

Correct Answer - C

Ans. C. Ecological study design

This is an example of an ecological study.

An ecological study is a type of Observational study where information is collected on a group (or population) rather than on individual members and then analyzed.

Here the association between a summary measure of sale of cigarettes (risk factor) and a summary measure of the number of cases of COPD(outcome) is studied.

112. A study was done to assess malnutrition among young children. 100 children were selected each from rural and urban areas. Out of these, 30 among rural and 20 among urban were found to be malnourished. which of the following statistical test is used to compare the data sets?

a) Paired t-test

b) Chi-square

c) The standard error of mean

d) ANOVA

Correct Answer - B

Ans. B. Chi-square test

Chi-square (χ^2) Test offers an alternate method of testing the significance of the difference between two proportions. It has the advantage that it can also be used when more than two groups are to be compared.

Park's PSM 24th ed. Page no. 889

113. The active disinfectant property of bleaching powder is due to:

a) Chlorine

b) Hypochloric acid

c) Hypochlorous acid

d) Chloramines

Correct Answer - C

Ans. C. Hypochlorous acid

Hypochlorous acid is the most effective form of chlorine for water disinfection.

The active component of bleaching powder, CaOCl_2 , is hypochlorous acid.

The disinfecting action of chlorine is mainly due to hypochlorous acid, and to a small extent due to the hypochlorite ions.

Park's PSM 24th ed. Page no. 138

114. Mother does not transmit what antibody to the baby –

a) Polio

b) Diphtheria

c) Diphtheria

d) Tetanus

Correct Answer - A

Ans. A. Polio

When given during pregnancy, the Tdap vaccine boosts antibodies in the mother, which are transferred to her developing baby. Early third-trimester administration optimizes neonatal antibody levels.

Ref. <https://www.ncbi.nlm.nih.gov/pmc/articles/PMC4168293/pdf/c> i

1)

115. Voluntary admission can be done maximum up to how much time according to MHA 2017

a) 48 hrs

b) 7 Days

c) 30 Days

d) 90 Days

Correct Answer - D

Ans. D. 90 Days

If admission requires more than 30 days or readmission within 7 days (section 90), they should be examined by two psychiatrists and can be admitted for a maximum period of 90 days if they satisfy norms as per this section of the act and have to inform the board for permission, taking account of AD and consent should be reviewed fortnightly along with planning for community-based treatment.

<http://www.amhonline.org/article.asp?issn=2589-9171;year=2018;volume=19;issue=1;spage=9;epage=14;aulast=Ne>

116. Blood bags are disposed of in

a) Yellow bag

b) Black bag

c) Red bag

d) White bag

Correct Answer - C

Ans : C. Red bag

The black bag is used for collecting dry waste material which is not infectious.

Materials like paper, plastics, cardboard boxes, and other dry waste generated in the hospital office or in the wards are disposed of in this bag.

This is not biomedical waste.

The red bag is used for the disposal of plastics collected from operation theaters, ICUs and wards.

The yellow bag is used for highly infectious items like a pathological waste, human anatomical waste such as body parts, amputated parts/organs, tumors, placentas, aborted or dead fetuses, blood-soaked cotton bandages, animal tissues, organs, carcasses, etc. Blue or White opaque bag is used for collecting the segregated metal sharps such as needles, blades, saws, scalpels, and glass pieces.

Ref Park 23/e p. 793-794]

117. Absolute contraindication for IUD (Intra Uterine Contraceptive Device) are all except –

a) Pregnancy

b) Undiagnosed vaginal bleeding

c) Pelvic inflammatory disease

d) Uterine malformation

Correct Answer - D

Ans. is 'd i.e., Uterine malformation

Contraindications

ABSOLUTE:

- Suspected pregnancy
- Pelvic inflammatory disease
- Vaginal bleeding of undiagnosed etiology
- Cancer of the cervix, uterus or adnexa and other pelvic tumours
- Previous ectopic pregnancy

RELATIVE :

- Anaemia
- Menorrhagia
- History of PID(Pelvic Inflammatory Disease) since last pregnancy
- Purulent cervical discharge
- Distortions of the uterine cavity due to congenital malformations, fibroid
- Unmotivated person

118. Which of the following is water-related disease

a) Yellow fever

b) Scabies

c) Cholera

d) Dysentery

Correct Answer - A

Ans. is 'a' i.e., Yellow fever

* *Water can* cause disease not only by drinking but also by various other modes, directly or indirectly.

* Depending upon the type of transmission, the diseases are classified.

* *Public Health Classification of Waterborne diseases*

* *Waterborne diseases*: Occur due to drinking contaminated water, transmitted by the faeco-oral route. Examples: Typhoid, Cholera. Dysentery, Viral Hepatitis A

* *Water washed diseases*: Include infections of the outer body surface which occur due to inadequate use of water or improper hygiene. Examples: Scabies, Trachoma, Typhus, Bacillary dysentery, Amoebic dysentery

* *Water-based diseases*: Refers to infections transmitted through an aquatic invertebrate animal. Examples: Schistosomiasis. Dracunculiasis (Guinea worm disease)

* *Water-related diseases (Water breeding diseases)*: Are infections spread by insects that depend on water. Examples: Malaria, Filariasis, Dengue, Yellow fever, Onchocerciasis

119. In Vision 2020, the target for Secondary Service center is for how much population –

a) 10000

b) 50000

c) 1 lac

d) 5 lac

Correct Answer - D

Ans is 'd' i.e. 5 lac

Vision 2020: The Right to Sight, is a global initiative launched by WHO in 1999 in a broad coalition with a 'Task Force of International Non-Governmental Organisations (NGOs)' to combat the gigantic problem of blindness in the world.

The objective is to eliminate avoidable blindness by the year 2020 and to reduce the global burden of blindness. The government of India has adopted 'Vision 2020: Right to Sight' under the National Programme for Control of Blindness.

Based on the recommendations of WHO, there is a need to develop the infrastructure pyramid which includes

1. Primary level Vision Centres

- There is a need to develop 20000 vision centers,
- Each with one Ophthalmic Assistant or equivalent (Community-based MLOP), Covering a population of 50000.

2. Service Centres.

- There is a need to develop 2000 service centers at the secondary level.
- Each with two ophthalmologists and 8 paramedics (Hospital-based

•

•

120. CA-125 is a marker for the screening of ovarian cancer. To characterize this test, histopathological confirmation of ovarian cancer was done in a cohort of patients. 60/100 women who tested positive for this test had ovarian cancer and 20/100 women who tested negative had ovarian cancer. What is the negative predictive value of this test?

a) 20/100

b) 40/100

c) 60/100

d) 80/100

Correct Answer - D

Ans: D. 80/100

- Negative predictive value (NPV): Ability of a screening test to identify correctly all those who don't have the disease, out of all those who test negative on a screening test.

		The Truth		
		Has the disease	Does not have the disease	
Test Score:	Positive	True Positives (TP) <div>a</div>	False Positives (FP) <div>b</div>	$PPV = \frac{TP}{TP + FP}$
	Negative	False Negatives (FN) <div>c</div>	True Negatives (TN) <div>d</div>	$NPV = \frac{TN}{TN + FN}$
		Sensitivity $\frac{TP}{TP + FN}$ Or, $\frac{a}{a + c}$	Specificity $\frac{TN}{TN + FP}$ $\frac{d}{d + b}$	

-
-
-

121. Screening is not useful in which carcinoma

a) Carcinoma prostate

b) Carcinoma colon

c) Carcinoma breast

d) Testicular tumor

Correct Answer - D

Ans: D. Testicular tumor

- Screening is not useful in testicular tumors.
- **Screening Recommendations for Asymptomatic Subjects:**
 - Breast:**
 - **Self-examination.**
 - Clinical examination.
 - Mammography.
 - MRI.
 - Cervical:**
 - Pap test (cytology).
 - HPV test
 - Colorectal:**
 - Sigmoidoscopy
 - Fecal occult blood testing (FOBT)
 - Colonoscopy
 - Fecal DNA testing
 - Fecal immunochemical testing (FIT)
 - CT colonography
 - Lung:**
 - Low-dose computed tomography
 - (CT) scan

-
-
-
-
-

122. Admission rate bias is?

a) Reporting bias

b) Response bias

c) Berksonian bias

d) None

Correct Answer - C

Ans. is 'c' i.e., Berksonian bias

Selection bias

Selection bias is distortion that results from the procedure used to select subjects and from factors that influence study participation. Groups to be compared are differentially susceptible to the outcome even before the experimental maneuver is performed.

Selection bias may be of the following types.

1. Surveillance/detection bias

- A potential artifact in epidemiologic data caused by the use of a particular diagnostic technique or type of equipment.
- For example, cancer rates may vary in different regions or periods, not because of an actual difference in the incidence of disease but because of different diagnostic technologies.

If the diagnostic test is being used in one region is more sensitive than other regions, the cancer rates will be high in that region even without the existence of an actual difference.

2. Neyman survival bias (Incidence-Prevalence bias)

- This type of bias is due to missing fatal cases, mild cases or cases of shorter duration from the study.
- For example, in a study of breast cancer, we can choose two different types of cases : ?
- Incident cases → All breast cancer patients newly diagnosed during

a given time.

- Prevalent cases → All breast cancer patients who are alive during a given time frame.
- These can lead to different results because the probability of finding a case in a given time frame is related to mortality risk. Those patients who have a mild form of the disease and survive for a relatively long time have a good chance of being around on the date of data collection. Those patients who die quickly are unlikely to be around on that date.

3. Referral bias or volunteer bias

- Volunteer or referral bias occurs because people who volunteer to participate in a study (or who are referred to it) are often different than non-volunteers/non-referral.
- This bias usually favours the treatment group, as volunteers tend to be more motivated and concerned about their health.

4. Response bias

- This occurs when those who respond to a survey differ in important ways from those who do not respond.
- This bias can work in either direction, i.e., if bias occurs, when those who do not respond to a survey differ in important ways from those who respond, it is called nonrespondent bias.

5. Berksonian bias

- Berksonian bias results from the greater probability of hospital admission for people with two or more diseases than for people with one disease. So, it is also known as admission rate bias.
- For example, If breast cancer is the exposure of interest (diseases are often treated as exposures in hospital-based case-control studies) and meningioma is the case disease then people with both breast cancer and meningioma could be hospitalized for either breast cancer or meningioma or both.
- However, people with only breast cancer or with the only meningioma could be hospitalized because of one of these diseases.
- Therefore, a greater proportion of people in the community with both breast cancer and meningioma would be admitted to the hospital than people with meningioma only.
- So, Berksonian bias occurs when both exposure (e.g., breast

123. Stimulation of the external auditory canal leads to cough due to which nerve

a) Auricular branch Vagus

b) Greater auricular nerve

c) Auriculotemporal nerve

d) Facial Nerve

Correct Answer - A

Ans: A. Auricular branch Vagus nerve.

>**Auricular branch of Vagus (Arnold's nerve)** and Facial nerve continues inwards to supply the posterior wall and floor of the EAC.

> The cough response caused while stimulating the ear canal is mediated by the vagus which also supplies the larynx.

(Re/. Shambaugh, 6th ed., page 45)

124.

widening of the cartilaginous part of the extra auditory canal called.

a) Otoplasty

b) Myringoplasty

c) Tympanoplasty

d) Meatoplasty

Correct Answer - D

Ans. (d) Meatoplasty.

Meatoplasty is an operative technique to widen the lateral cartilaginous part of the external auditory canal.

Otoplasty- is a procedure to change the shape, position or size of the ears.

Myringoplasty-closure of the perforation of pars tensa of the tympanic membrane

Tympanoplasty- surgical technique to repair a defect in the tympanic membrane with the placement of a graft, either medial or lateral to the tympanic membrane annulus

ref: <https://vula.uct.ac.za/access/content/group/ba5fb1bd-be95-48e5-81be-586fbaeba29d/Meatoplasty.pdf>

125. Tubercular Otitis media is characterized by all except

- a) Painful otorrhea
- b) Multiple perforations
- c) Pale granulations
- d) Foul-smelling ear discharge

Correct Answer - A

Ans. A. Painful otorrhea.

>Tuberculosis of middle ear is a comparatively rare entity usually seen in association with or secondary to pulmonary tuberculosis, the infection reaches the middle ear through the eustachian tube

>It is characterized by painless otorrhoea which fails to respond to the usual antimicrobial treatment

>patient with evidence of tubercle infection elsewhere followed by multiple tympanic membrane perforations, abundant granulation tissue, and bone necrosis, preauricular lymph node enlargement

<https://www.ncbi.nlm.nih.gov/pubmed/21522113>

126. Partial and full closure done in

a) Atrophic rhinitis

b) Allergic rhinitis

c) Vasomotor rhinitis

d) Occupational rhinitis

Correct Answer - A

Ans. A. Atrophic rhinitis

ATROPHIC RHINITIS

>It is a form of chronic rhinitis associated with atrophy of nasal mucosa, mucous glands, nerves, and vessels.

>It can be primary or secondary.

>The surgical options aim to reduce the size of the roomy cavities to prevent the exposure to drying effects of air and crusts formation and thus help regeneration of nasal mucosa.

Full closure - Young's operation

Partial closure - Modified young's operation.

(Ref. Cummings,6th ed., 695)

127. Occipitomenal view of PNS X-ray called as

a) Caldwell view

b) Water view

c) Town view

d) Pine view

Correct Answer - B

Answer:b. Water view

Occipitomenal view of PNS X-ray called as Water view

128. What causes shifting fluid?

- a) Exudative Retinal detachment
- b) Tractional Retinal Detachment
- c) Rhegmatogenous retinal detachment
- d) Retinodialysis

Correct Answer - A

Ans.a.Exudative Retinal detachment.

>In exudative retinal detachment, the subretinal fluid may be confined to a localized area, usually the posterior pole, or may extend to the periphery, even forming bullous retinal detachment.

>**The characteristic feature of a significant exudative retinal detachment is the presence of shifting subretinal fluid.**

>The fluid shifts to the most dependent location when patients change body position.

<https://clinicalgate.com/nonrhegmatogenous-retinal-detachment/>

129. Conjunctival injection, pharyngeal injection, polymorphic rash, cervical lymphadenopathy can be seen in

a) Kawasaki syndrome

b) Measles

c) Thrombocytopenia

d) Mumps

Correct Answer - A

Ans: a.Kawasaki syndrome.

>Kawasaki disease is a generalized vasculitis that affects medium-sized arteries.

> It is characterized by systemic inflammation that manifests as persistent fever, erythema of the mucous membranes, bilateral nonexudative conjunctivitis, rash, swelling and redness of the hands and feet, and cervical lymphadenopathy

Ref:<https://www.ncbi.nlm.nih.gov/pmc/articles/PMC3034467/>

130. Incongruous Homonymous hemianopia with Wernicke's hemianopia pupil is seen with the lesion of

- a) Optic radiation
- b) Lateral geniculate body
- c) Optic tract
- d) Anterior occipital cortex

Correct Answer - C

Ans:c. Optic tract

>Anterior optic tract lesion produces Incongruous Homonymous hemianopia, decreased visual acuity, afferent pupil defect(Wernicke's hemianopia pupil) and atrophy of optic discs with characteristic Bow-tie atrophy are contralateral.

>A complete Homonymous hemianopia results from posterior optic tract lesions.

Ref:[https://books.google.co.in/books?](https://books.google.co.in/books?id=bDpl9n4q3e0C&pg=PA376&lpg=PA376&dq=Incongruous+HomofCi_bmAhUoxzgGHf56An8Q6AEwFXoECAoQAQ#v=onepage&q=In)

[id=bDpl9n4q3e0C&pg=PA376&lpg=PA376&dq=Incongruous+HomofCi_bmAhUoxzgGHf56An8Q6AEwFXoECAoQAQ#v=onepage&q=In](https://books.google.co.in/books?id=bDpl9n4q3e0C&pg=PA376&lpg=PA376&dq=Incongruous+HomofCi_bmAhUoxzgGHf56An8Q6AEwFXoECAoQAQ#v=onepage&q=In)

131. The patient came with proptosis, restriction of eye movements, and was Euthyroid. What could this be from?

a) Orbital Cellulitis

b) Orbital Lymphoma

c) Orbital pseudotumor

d) Thyroid ophthalmopathy

Correct Answer - C

Ans: C.Orbital pseudotumor

>Proptosis and restricted eye movement is most commonly associated with thyroid ophthalmopathy

>But in question asked is Euthyroid.

>So, the best option to select is Orbital pseudotumor(Idiopathic orbital inflammatory syndrome)

Ref. Comprehensive Ophthalmology by AK Khurana - 6th Edition Page no 335

132. Prerequisite for sympathetic ophthalmitis

a) Penetrating injury to the eye

b) Blunt ocular tumor

c) Chemical injury

d) Urinary tract infection

Correct Answer - A

Ans: a. Penetrating injury to the eye.

>Sympathetic ophthalmia is a rare type of uveitis that causes small abnormal clumps of cells (granulomas) to form.

>This disorder occurs in the uninjured eye after a penetrating injury (such as when a pencil, pen, or stick punctures the eye) or surgery to the other (injured) eye.

Ref:<https://www.msdmanuals.com/en-in/home/eye-disorders/uveitis-and-related-disorders/sympathetic-ophthalmia>.

133. Photostress test to differentiate

- a) Lens and cornea
- b) The macula and Optic nerve diseases
- c) Cataract and glaucoma
- d) Retinal and vitreous diseases

Correct Answer - B

Ans:b.The macula and Optic nerve diseases.

>To distinguish optic nerve conduction defects from the macular disease in patients with otherwise unexplained loss of central vision we first determined the best visual acuity with correction at distance in unilateral defects.

> The normal eye was tested first and **photo stressed for ten seconds** by looking at an ordinary penlight held 2 to 3 cm from the eye.

>The time required to read three letters on three **Snellen test** lines just larger than the best acuity was used as the endpoint.

>Recovery time will be prolonged with maculopathy.

>Prolonged recovery time will not be observed in patients who have optic nerve disease.

<https://www.ncbi.nlm.nih.gov/pubmed/836667>

134. Which layer of cornea helps in the hydration of stroma of cornea

a) Endothelium

b) Epithelium

c) Descemet membrane

d) Stroma

Correct Answer - A

Ans: a.Endothelium

>The corneal endothelium is responsible for maintaining the hydration of the cornea.

> This is through a "Pump-Leak" mechanism where the active transport properties of the endothelium represent the "Pump" and the stromal swelling pressure represents the "Leak"

Ref:https://www.researchgate.net/publication/51238307_Molecular_Me

135. A 65 old male with a history of hypertension and diabetes, presents to the OPD with complaints of diplopia and squint. On examination, the secondary deviation is more than the primary deviation. Which of the following is most likely diagnosis

a) concomitant squint

b) paralytic squint

c) Restrictive squint

d) Pseudo squint

Correct Answer - B

Ans:b.paralytic squint.

>Paralytic or incomitant squint occurs when there is an acquired defect of the movement of an eye.

> The squint (and double vision) is maximally demonstrated by looking in the direction of action of the weakened muscle.

>Paralytic squints occur due to disease of the III, IV and VI cranial nerves.

Ref:<https://www.gponline.com/basics-strabismus/ophthalmology/article/1055827>

136. Esotropia is common in

a) Myopia

b) Hypermetropia

c) Emmetropia

d) Astigmatism

Correct Answer - B

And: B. Hypermetropia

>Patients with refractive esotropia are typically farsighted (hyperopic).

> This means that the eyes must work harder to see clearly, particularly when the object of regard is up close._

<https://aapos.org/glossary/accommodative-esotropia>

137. An extra row of cilia posterior to the grey line

a) Distichiasis

b) Tylosis

c) Madarosis

d) Trichiasis

Correct Answer - A

And: a. Distichiasis

>Distichiasis is a rare disorder defined as the abnormal growth of lashes from the orifices of the meibomian glands on the posterior lamella of the tarsal plate.

Ref:<https://emedicine.medscape.com/article/1212908-overview>

138. The patient came with unilateral Proptosis and bilateral Abducent nerve palsy. This could be from

a) Cavernous sinus

b) Orbital cellulitis

c) Orbital pseudotumor

d) Orbital lymphoma

Correct Answer - A

Ans: a.Cavernous sinus

>Proptosis is initially seen unilaterally ultimately becomes bilateral.
>6th cranial nerve(Abducent) passes through the cavernous sinus.so in cavernous sinus thrombosis bilateral abducens palsy is seen.

Parson's Diseases of the Eye -Ed. 22 Pg 497

139. The characteristic finding of fungal ulcers?

a) Satellite lesions

b) Dendritic ulcer

c) Ring abscess

d) White hypopyon

Correct Answer - A

And.a.Satellite lesions

>Fungal keratitis or keratomycosis refers to an infective process of the cornea caused by any of the multiple pathologic fungi capable of invading the ocular surface.

>when the epithelial integrity is broken either due to trauma or ocular surface disease and the organism gains access into the tissue and proliferates.

>Multifocal stromal infiltrates or "satellite lesions" have been considered a characteristic feature of fungal keratitis.

Ref: https://eyewiki.aao.org/Fungal_Keratitis

140. A drug used in a patient with increased IOP and optic disc changes, ciliary congestion for decrease IOP acts by increasing uveoscleral outflow is

a) Latanoprost

b) Pilocarpine

c) Dorzolamide

d) Timolol

Correct Answer - A

Ans: a. Latanoprost

>Latanoprost selectively stimulates the prostaglandin F2 alpha receptor and this results in a decreased intraocular pressure (IOP) via the increased outflow of aqueous humor, which is often implicated in cases of elevated intraocular pressure.

Ref:[https://www.google.com/url?](https://www.google.com/url?sa=t&source=web&rct=j&url=https://www.drugbank.ca/drugs/DB00654)

[sa=t&source=web&rct=j&url=https://www.drugbank.ca/drugs/DB00654](https://www.drugbank.ca/drugs/DB00654)

[Nz08_cOFzeYemAzeVf&cshid=1578651404060](https://www.drugbank.ca/drugs/DB00654)

&

141. A patient diagnosed with Rheumatoid arthritis was on medications. After 2 years, he developed a blurring vision and was found to have corneal opacity. Which drug is most likely to cause this?

a) Sulfasalazine

b) Chloroquine

c) Methotrexate

d) Leflunomide

Correct Answer - B

Ans: B. Chloroquine

In long-term chloroquine therapy Ocular complications were observed

>This therapy is usually used in patients with rheumatoid arthritis, lupus erythematosus, sarcoidosis, discoid lupus, and other chronic "collagen disease".

>Retinal changes, corneal opacifications, blurring of vision are some complications seen in long term use of Chloroquine.

Ref: <https://www.ncbi.nlm.nih.gov/pubmed/1427503>

142. Nutcracker esophagus, the correct statement is

- a) There is extremely forceful peristaltic activity leading to episodes of chest pain and dysphagia
- b) There is no medical t/t available
- c) Type of oesophageal Malignancy
- d) None

Correct Answer - A

Ans: A. There is extremely forceful peristaltic activity leading to episodes of chest pain and dysphagia

NutCracker Oesophagus is a hypermotility disorder with high amplitude peristalsis. It is a condition in which extremely forceful peristaltic activity leads to episodic chest pain and dysphagia.

Treatment is with nitrates or nifedipine.

Ref. davidsons principles and practice 23rd edition page no.795

143. Which of the following criteria is used to assess the prognosis of the liver condition as represented in the picture below?

a) Child pugh score

b) Milan score

c) Meld score

d) Alvarado score

Factor	1 point	2 points	3 points
Total bilirubin (μmol/L)	<34	34-50	>50
Serum albumin (g/L)	>35	28-35	<28
PT INR	<1.7	1.71-2.30	>2.30
Ascites	None	Mild	Moderate to Severe

Hepatic encephalopathy	None	Grade I-II (or suppressed with medication)	Grade III-IV (or refractory)
------------------------	------	--	------------------------------

Interpretation:

Points	Class	One year survival	Two-year survival
5–6	A	100%	85%
7–9	B	81%	57%
10–15	C	45%	35%

144. Sudden onset headache with neck rigidity?

a) Intraparenchymal hemorrhage

b) Subarachnoid hemorrhage

c) Meningitis

d) None of the above

Correct Answer - B

Ans: b. Subarachnoid hemorrhage

sudden onset of a severe headache (often described as "the worst headache of my life")

nausea and vomiting

stiff neck

sensitivity to light (photophobia)

blurred or double vision

loss of consciousness

seizures

145. Vegetation in mitral valve seen in which condition

a) Libman sacks

b) Infective endocarditis

c) NBTE

d) Rheumatic fever

Correct Answer - B

Ans: B. Infective endocarditis

Infective endocarditis is characterized by lesions, known as vegetations, which is a mass of platelets, fibrin, microcolonies of microorganisms, and scant inflammatory cells. In the subacute form of infective endocarditis, the vegetation may also include a center of granulomatous tissue, which may be fibrosed or calcified.

146. Water hammer pulse is seen in

- a) Aortic regurgitation
- b) Mitral stenosis
- c) Aortic stenosis
- d) Left ventricular failure

Correct Answer - A

Ans: A. Aortic regurgitation

Water hammer pulse

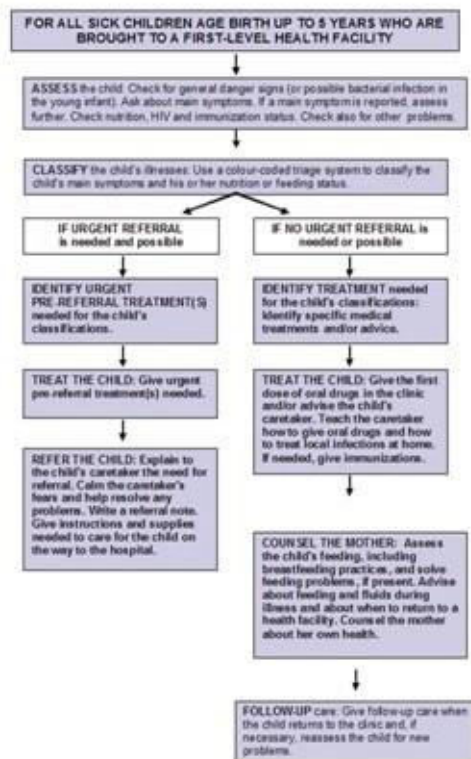
- It is a large bounding pulse, associated with an increased stroke volume of the left ventricle and a decrease in the peripheral resistance, leading to wide pulse pressure.
- The pulse strikes the palpating finger with a rapid, forced jerk and quickly disappears.
- It is best felt in the radial artery with the patient's arm elevated.
- It is seen in aortic regurgitation.

147. What will you do when 3 yrs old child parents come to phc with fever, cough since 5 days with chest indrawing present under mnci classification

- a) Give antipyretics only
- b) Give antibiotics and follow up
- c) Refer urgently to tertiary care
- d) Give antibiotics and refer to tertiary care

Correct Answer - D

Ans: D. Give antibiotics and refer to tertiary care



148. What poison will you detect in skeleton even after emaciation

a) Lead

b) Arsenic

c) Mercury

d) Cadmium

Correct Answer - B

Ans: B. Arsenic

Arsenic can be detected even in conflagrated human bones. Hence, it is possible to detect poisoning by arsenic even when the body has been burnt for a long time.

FMT 2nd edition Page no. 184

**149. Ph7.2, HCO_3^- - (10 or 12), pCO_2 -35 ,
metabolic acidosis due to**

a) K^+ excretion by the kidney

b) CO_2 expiration by lungs

c) H^+ excretion by the kidney

d) HCO_3^- loss by kidney

Correct Answer - D

Ans: D. HCO_3^- loss by kidney

In the question, pH is decreased (acidosis) & pCO_2 is decreased (Normal= 40-45 mm Hg).

A decreased pCO_2 will try to increase pH, hence it must be a secondary compensating mechanism.

So, the primary mechanism causing the acid-base imbalance must be a decrease in serum bicarbonate concentration i.e. metabolic acidosis.

150. Impaired function of Aquaporin results in

a) Liddle syndrome

b) Nephrogenic DI

c) Cystic fibrosis

d) Barter syndrome

Correct Answer - B

Ans: B. Nephrogenic DI

Aquaporins, also called **water channels**, are integral membrane proteins from a larger family of major intrinsic proteins that form pores in the membrane of biological cells, mainly facilitating the transport of water between cells.

Genetic defects involving aquaporin genes have been associated with several human diseases including nephrogenic diabetes insipidus and neuromyelitis optica.

151. Most serious complication of measles is:
September 2008

a) Croup

b) Meningo-encephalitis

c) Otitis media

d) Pneumonia

Correct Answer - B

Ans. B: Meningo-encephalitis

Measles is a highly communicable acute disease. It is also known as rubeola and is marked by prodromal fever, cough, coryza, conjunctivitis, and pathognomonic enanthem (i.e., Koplik spots), followed by an erythematous maculopapular rash on the third to seventh day.

Infection confers life-long immunity.

A generalized immunosuppression that follows acute measles frequently predisposes patients to bacterial otitis media and bronchopneumonia.

In approximately 0.1% of cases, measles causes acute meningo-encephalitis, which is the most serious complication. Subacute sclerosing panencephalitis (SSPE) is a rare chronic degenerative disease that occurs several years after measles infection.

152. The most common cause of death in SLE in children

a) Lupus nephritis

b) Lupus cerebritis

c) Libman sacks endocarditis

d) Anemia and infections

Correct Answer - A

Ans: A. Lupus nephritis

Major causes of death in pediatric SLE include :

. Renal disease (lupus nephritis)

. Severe disease flare

. Infections

153. A patient having multiple Gall stones and shows 8 mm dilation and 4 stones in CBD, best treatment modalities are –

a) Cholecystectomy with choledocholithotomy at the same setting

b) ESWL

c) Cholecystectomy and wait for ERCP

d) All

Correct Answer - A

Ans: A. Cholecystectomy with choledocholithotomy done at the same sitting

Management of suspected or proven CBD stones associated with gall bladder stones

- For gallstones - *laparoscopic cholecystectomy is the procedure of choice.*
- For CBD stones two things can be done:
 - 1) If the surgeon is experienced in laparoscopic techniques of CBD stone removal then both cholecystectomy and choledocholithotomy are done in the same sitting.
- CBD stones are first confirmed by an intraoperative cholangiogram
- then the stones are removed laparoscopically via the cystic duct or by choledochotomy.
- 2) If the surgeon is not experienced with laparoscopic methods of CBD stone removal, preoperative endoscopic sphincterotomy with stone removal and later laparoscopic cholecystectomy is done.
- Laparoscopic cholecystectomy with choledocholithotomy in the same sitting is the preferred technique (provided the surgeon is experienced)

•

154. Pulmonary plethora is seen with all except:

a) TGS

b) Ebstein anomalies

c) Hypoplastic left heart syndrome

d) Double outlet right ventricle

Correct Answer - B

Ans: B. Ebstein anomalies

Pulmonary plethora is seen in

- TOF
- TA
- Ebstein's anomaly
- Pulmonary atresia

155. 20 years old man presented with the complaint of swelling of the wrist for the last two years. histopathological examination showed spindle-shaped cells and verocay bodies what is the diagnosis?

a) Lipoma

b) Dermoid cyst

c) Neuro fibroma

d) Schwannoma

Correct Answer - D

Ans: D. Schwannoma

spindle cells and verocay bodies are seen in schwannoma is a tumor of the tissue that covers nerves, called the nerve sheath. These tumors develop from a type of cell called a Schwann cell, which gives them their name. Schwannomas are often not cancerous (benign).

The most common type of schwannoma is vestibular schwannoma. It affects the nerve responsible for balance (also called the vestibular nerve). It can cause inner ear deafness because the hearing and balance nerve run together, and as the tumor grows it damages the hearing nerve (cochlear nerve). Because of this doctor used to call them acoustic neuromas.

Microscopically, the tumor is composed of fibrocellular bundles forming the whorled pattern.

There are areas of dense and compact cellularity (Antoni A

156. Hemodynamically unstable patient with SVT

a) IV IBUTILIDE

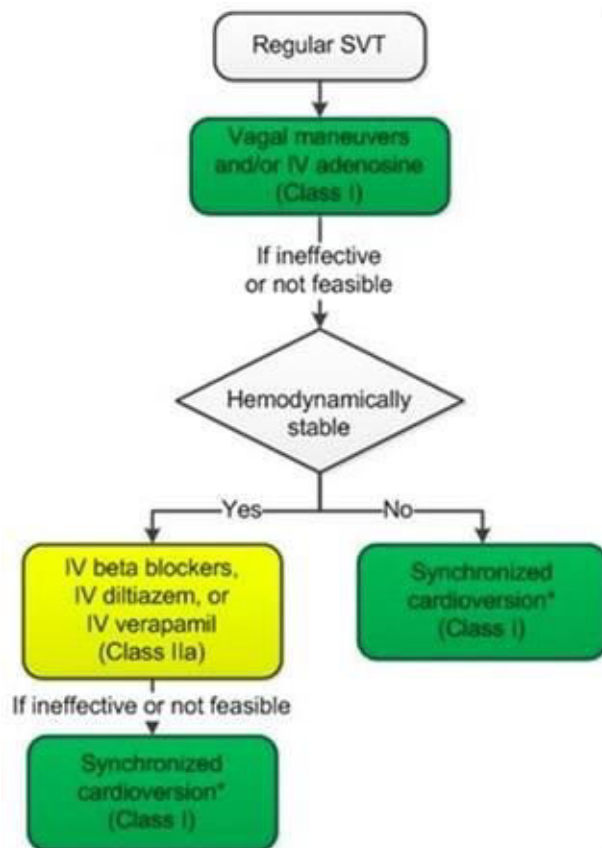
b) IV DILTIAZEM

c) CARDIOVERSION

d) Iv beta-blockers

Correct Answer - C

Ans: C. CARDIOVERSION



157. A Female patient was on lithium for bipolar disorder for 6 months. she fasted for some days due to religious condition and later presented with seizures, tremors, confusion and weakness. What investigations have to be done to diagnose her condition

a) serum electrolytes

b) serum lithium

c) ECG

d) MRI

Correct Answer - B

Ans: B. serum lithium

Because of its effects on multiple body systems, including but not limited to renal, hematologic, and thyroid systems, appropriate baseline studies must precede the start of lithium therapy.

The minimal tests to be done include serum creatinine, electrolytes, thyroid function tests, and a complete blood count with differential. Additionally, because of its cardiac effect, an ECG is indicated. Any woman thought to be pregnant should have a pregnancy test.

Ref: Nurcombe B. (2008). Chapter 12. Diagnostic Formulation, Treatment Planning, and Modes of Treatment in Children and Adolescents. In M.H. Ebert, P.T. Loosen, B. Nurcombe, J.F. Leckman (Eds), CURRENT Diagnosis & Treatment: Psychiatry, 2e.

158. Lithium causes:

a) Hypokalemia

b) Hyperkalemia

c) Hypocalcemia

d) Hypercalcemia

Correct Answer - A

Ans: A. Hypokalemia

Side effects of lithium

Neurological: - *Tremor is the commonest side effect of lithium.* Other CNS side effects are giddiness, ataxia, motor incoordination, hyperreflexia, mental confusion, nystagmus.

Renal: - Nephrogenic diabetes insipidus with polyuria & polydipsia. Amiloride is the DOC for Lithium induced nephrogenic DI.

Cardiovascular: - Effects are similar to hypokalemia. *The most common ECG change is T wave depression.*

Endocrine: - Goitre, *hypothyroidism*

GIT: - Nausea, vomiting, diarrhea, metallic taste, abdominal pain.

Dermatological : - Acneiform eruptions, papular eruption, exacerbation of psoriasis.

Teratogenicity: - Ebstein's anomaly in the fetus.

159. A 50-year-old man presents with paresthesia. HB-6.8g/dl. Peripheral smear shows macrocytosis and neutrophils with hypersegmented nuclei. endoscopy reveals atrophic gastritis. a most probable diagnosis is

a) Folate deficiency

b) Vitamin B12 deficiency

c) Riboflavin deficiency

d) Iron deficiency

Correct Answer - B

Ans: B. Vitamin B12 deficiency

Macrocytosis and hyper segmented neutrophils on peripheral smear, poor absorption (Atrophic gastritis) suggest the diagnosis of B12 deficiency.

The presence of anemia (Hb= 6gm%) Macrocytosis (MCV=104) and decreased vitamin B12 levels (B12=60 pg/ml) suggests a diagnosis of megaloblastic anemia due to vitamin B12 deficiency.

The patient in question thus has macrocytic anemia due to vitamin B12 deficiency.

160. All trans retinoic acid is used in the treatment of tumour associated with

a) BCR-ABL

b) PML-RARA

c) CMYC

d) CEBPA

Correct Answer - B

Ans: B. PML-RARA

- All-trans retinoic acid (ATRA) is an active metabolite of vitamin A under the family retinoid.
- Retinoids, through their cognate nuclear receptors, exert potent effects on cell growth, differentiation and apoptosis, and have significant promise for cancer therapy and chemoprevention.
- Differentiation therapy with ATRA has marked a major advance and become the first choice drug in the treatment of acute promyelocytic leukemia (APL).
- All-trans retinoic Acid is used in the treatment for Acute Promyelocytic Leukemia (PML)

**161. Renal tubular acidosis with ABG value
pH = 7.24 P_{O_2} = 80; P_{aCO_2} = 36 Na = 131;
 HCO_3^- = 14 Cl = 90; BE = -13 Glucose =
135 above ABG picture suggest –**

a) Respiratory acidosis

b) Respiratory alkalosis

c) Metabolic acidosis

d) Metabolic alkalosis

Correct Answer - C

Ans: C. Metabolic acidosis

The given values have low pH, and low HCO_3^- Indicate metabolic acidosis

PCO_2 in lower normal range (normal value 35-45 mm/hg)

162. Patient with pulmonary fibrosis. Which antiarrhythmic drug should not be given

a) Amiodarone

b) Flecainide

c) Iv ibutilide

d) lidocaine

Correct Answer - A

Ans: A. Amiodarone

Amiodarone and its metabolites can produce lung damage directly by a cytotoxic effect and indirectly by an immunological reaction. The latter is supported by the finding of cytotoxic T cells in bronchoalveolar lavage (BAL) fluid from patients with diagnosed APT. Amiodarone may induce the production of toxic O₂ radicals, which can directly damage cells

163. A 42-year-old patient with obstructive jaundice. Alp, Ggt, haptoglobin all increased. The most likely cause is:

a) Alcohol

b) Lead

c) Chronic rf

d) None of the above

Correct Answer - A

Ans: A. Alcohol

An indicator that should make the clinician highly suspicious of alcohol-related liver injury is AST: ALT ratio of 2:1 or more.

Gamma-glutamyl transferase (GGT) is another sensitive but non-specific marker for the hepatic injury which cannot be used solely to diagnose alcohol-related hepatic insult.

Levels of GGT greater than twice the normal values in addition to AST:ALT ratio >2 strongly indicate alcohol-induced liver injury as well.

164. The differentiating feature between IBS and organic GI disease is:

a) Diarrhea

b) Stool calprotectin

c) Pain abdomen

d) Mucus in stools

Correct Answer - B

Ans: B. Stool calprotectin

Both organic IBD and non-organic functional disorders like IBS exhibit very similar symptoms researchers have identified several stool-based biomarkers to differentiate between IBD and IBS. These become especially crucial when taking the next step towards deciding how to manage the disease (e.g. therapeutic intervention, etc.). Those biomarkers include the following:

- Calprotectin
- Alpha-1 Antitrypsin
- Lysozyme
- Secretory IgA
- Albumin

165. Patient has fatigue. But not gaining weight. Body was warm. Investigation will show:

a) Low TSH with more t3 or t4

b) High TSH with normal t3 or t4

c) High TSH with euthyroid

d) Increased uptake of t3, but decrease t4

Correct Answer - A

Ans: A. Low TSH with more t3 or t4

166. Warming in Frost frostbite should be done at what temperature:

a) 37 degree

b) 42 degree

c) 44 degree

d) 46 degree

Correct Answer - A

Ans: A. 37 degree

At temperature below freezing (dry-cold condition) frostbite occurs the tissue freeze & ice crystals form in between the cells

Affected part should be warmed using water at 44 °is under

Criticism, Warming should last about 20 minutes at a time, Intake of hot fluids promotes general rewarming

167. Which of the following is not seen in Pituitary apoplexy

a) Headache

b) Hypertension

c) Hypotension

d) Vomiting

Correct Answer - C

Ans: C. Hypotension

Following are seen in Pituitary apoplexy

- Severe hypoglycemia
- Severe headache (usually retro-orbital)
- Impaired consciousness
- Fever
- Visual disturbances (visual field defect, visual acuity)
- Ophthalmoplegia (ocular paresis) → Causing diplopia
- Hypotension & shock
- Nausea/vomiting
- Meningeal sign

168. Loss of pain/temperature sensation on ipsilateral face & C/L body due to thrombosis in

a) PICA

b) Posterior cerebellar artery

c) Superior cerebellar artery

d) None of the above

Correct Answer - A

Ans: A. PICA

.Most cases result from ipsilateral vertebral artery occlusion; occlusion of the posterior inferior cerebellar artery is responsible for it.

Vessel occlusion that results in Lateral Medullary syndrome:

- Vertebral (most common)
- Posterior inferior cerebellar (2nd most common)
- Superior, middle or Inferior lateral medullary arteries

Lateral medullary syndrome (Wallenberg syndrome):

- Vertigo
- Numbness of ipsilateral face and contralateral limbs
- Diplopia
- Dysphagia
- Dysarthria
- Ataxia
- Hoarseness

169. All found in LVF except

a) Lung oligemia

b) Kerley b lines

c) Rales

d) Pedal edema

Correct Answer - A

Ans: A. Lung oligemia

Chest X-ray Features of Left ventricular failure:

- Cardiomegaly
- Kerley lines
- Prominent upper lobe veins
- Bat's wings shadow
- Pleural effusion

Kerley B line is due to interstitial edema.

Prominent right descending pulmonary artery is seen in acute pulmonary embolism.

170. All of the following show low glucose in pleural fluid, EXCEPT-

a) Empyema

b) Malignant pleural effusion

c) Rheumatoid arthritis

d) Dressler's syndrome

Correct Answer - D

Answer is **D** (Dressler's Syndrome):

Dressler syndrome is a secondary form of pericarditis that occurs in the setting of injury to the heart or the pericardium (the outer lining of the heart). It consists of fever, pleuritic pain, pericarditis and/or pericardial effusion.

The disease consists of persistent low-grade fever, chest pain (usually pleuritic), pericarditis and/or pericardial effusion. The symptoms tend to occur 2–3 weeks after myocardial infarction but can also be delayed a few months. It tends to subside in a few days, and very rarely leads to pericardial tamponade. Elevated ESR is an objective but nonspecific laboratory finding.

Dressler's Syndrome is not associated with low glucose in pleural fluid.

Rheumatoid Arthritis, Malignancy and Empyema (Bacterial infections) are all established causes of pleural effusion with low glucose.

Pleural effusion with low glucose (< 60 mg/dl)

· Malignancy

· Bacterial infections

· Rheumatoid pleuritis

171. A 25 years old lady with a history of fever for 1 month presents with headache and ataxia. Brain imaging shows dilated ventricles and significant basal exudates. Which of the following will be the most likely CSF finding:

a) Lymphocytosis, Low Glucose, High protein

b) Lymphocytosis, Normal Glucose, High protein

c) Lymphocytosis, Low Glucose, Normal protein

d) Neutrophilia, Low glucose, Low Protein

Correct Answer - A

Ans: A. (Lymphocytosis, Low Glucose, High protein)

Presence of significant basal exudates, together with dilated ventricles (hydrocephalus) in a young female with a prolonged history of fever and headache suggests a diagnosis of Tubercular Meningitis.

Tubercular Meningitis is characterized by Lymphocytic Pleocytosis, Low Glucose and High Protein within the CSF.

The pathological hallmark of Tubercular Meningitis is the predominant involvement of basal cisterns that are observed by the presence of basal inflammatory tissue exudate.

172. Which of the following drug can be given in patients of primary pulmonary hypertension?

a) Icatibant

b) Bosentan

c) Labetolol

d) Sodium nitroprusside

Correct Answer - B

Answer- B. Bosentan

Treatment for Primary pulmonary hypertension:

CALCIUM CHANNEL BLOCKERS:

- Patients who respond to short-acting vasodilators at the time of cardiac catheterization should be treated with calcium channel blockers.
- The endothelin receptor antagonists bosentan and ambrisentan are approved treatments of PAH
- Bosentan is contraindicated in patients who are on cyclosporine or glyburide concurrently.

173. A patient arrived in ER following an RTA with hypotension, respiratory distress and subcutaneous emphysema with no entry of air on one side. What will be the best management?

- a) Needle decompression in 5th intercostal space in the midaxillary line
- b) Continue PPV
- c) Shift to ICU and incubate
- d) Secure IV line and start fluid resuscitation after insertion of the wide-bore IV line

Correct Answer - A

Ans- A. Needle decompression in 5th intercostal space in the midaxillary line

A tension pneumothorax develops when a 'one-way valve' air leak occurs either from the lung or through the chest wall.

Air is sucked into the thoracic cavity without any means of escape, completely collapsing then compressing the affected lung.

Etiology-

- The most common causes are penetrating chest trauma, blunt chest trauma with parenchymal lung injury and air leak that did not spontaneously close, iatrogenic lung injury (e.g. due to central venepuncture) and mechanical positive pressure ventilation.

C/F-

- The patient is increasingly restless with tachypnoea, dyspnoea and distended neck veins

•

174. Treatment of Renal cell carcinoma of less than 4 cm will be-

- a) Partial nephrectomy
- b) Radical nephrectomy
- c) Radical nephrectomy + postoperative radiotherapy
- d) Radical nephrectomy + chemotherapy

Correct Answer - A

Ans: A. Partial nephrectomy

Partial nephrectomy is now being used as primary surgical therapy for patients with a tumor less than 4 cm in size. Earlier Radical nephrectomy was the treatment of choice for tumors of any size.

- Classic radical nephrectomy consists of removal of the kidney, perirenal fat, adrenal gland, and regional lymph nodes. Most stage I and stage II tumors.
- Partial nephrectomy- is indicated for patients with a T1 tumor (according to the UICC TNM staging system) and a normal contralateral kidney.
- Intervention should be considered for growth to >3-4cm or by >0.5cm per year.

T0	No evidence of primary tumour.
T1	Tumour ≤ 7 cm in greatest dimension, limited to the kidney.
T1a	Tumour ≤ 4 cm in greatest dimension, limited to the kidney.
T1b	Tumour > 4 cm but not > 7 cm in greatest dimension, limited to the kidney.
T2	Tumour > 7 cm in greatest dimension, limited to the kidney.
T2a	Tumour > 7 cm but ≤ 10 cm in greatest dimension, limited to the kidney.
T2b	Tumour > 10 cm, limited to the kidney.
T3	Tumour extends into major veins or perinephric tissues but not into the ipsilateral adrenal gland and not beyond Gerota fascia.
T3a	Tumour grossly extends into the renal vein or its segmental (muscle containing) branches, or tumour invades perirenal and/or renal sinus fat but not beyond Gerota fascia.
T3b	Tumour grossly extends into the vena cava below the diaphragm.
T3c	Tumour grossly extends into the vena cava above the diaphragm or invades the wall of the vena cava.
T4	Tumour invades beyond Gerota's fascia (including contiguous extension into the ipsilateral adrenal gland).

AJCC: American Joint Committee on Cancer; T: primary tumour; N: regional lymph nodes; M: distant metastasis. Taken from Edge SB, American Joint Committee on Cancer.²⁴

Stage T1aN0M0

- Partial nephrectomy recommended. This can be done via open/laparoscopic/robotic procedures

Stage T1bN0M0

- PN (open/laparoscopic/robotic) in cases where technically feasible
- Laparoscopic RN should be offered if a PN is not feasible
- Open RN if laparoscopic surgery is not possible.

Stage T2N0M0

- RN – open/laparoscopic/robotic
- PN – open/laparoscopic/robotic

Stage T3

- RN – open, laparoscopic or robotic-assisted
- Resection of vascular thrombosis when applicable (usually open)
- Resection of all gross disease including hilar or retroperitoneal extension
- PN may be attempted in highly selected cases by experienced surgeons

Ref- Bailey and Love, Short practice of surgery, 27th edition published in 2018 Pg 1420

https://www.researchgate.net/publication/263933944_Surgical_ma

175. Which is not seen in Asepsis score-

a) Erythema

b) Induration

c) Serous discharge

d) Purulent exudate

Correct Answer - B

Answer- B. Induration

Criterion	Points
Additional treatment	0
Antibiotics for wound infection	10
Drainage of pus under local anaesthesia	5
Debridement of wound under general anaesthesia	10
Serous discharge	Daily 0-5
Erythema	Daily 0-5
Purulent exudate	Daily 0-10
Separation of deep tissues	Daily 0-10
Isolation of bacteria from wound	10
Stay as inpatient prolonged over 14 days as result of wound infection	5

Ref- Bailey and Love, Short practice of surgery, 27th edition published in 2018 Pg 48

176. Esophageal manometry was performed - it revealed panesophageal pressurization with distal contractile integrity as >450mm Hg pressure in the body. What will be the diagnosis?

a) Type 1 achalasia

b) Type 2 achalasia

c) Type 3 achalasia

d) Jackhammer esophagus

Correct Answer - C

Ans: C. Type 3 achalasia

Type I achalasia (classic achalasia)-

- Elevated median IRP (>15 mmHg), 100% failed peristalsis (DCI <100 mmHg.s.cm)
- Premature contractions with DCI values <450 mmHg.s.cm satisfy criteria for failed peristalsis

Type II achalasia (with esophageal compression)-

- Elevated median IRP (>15 mmHg), 100% failed peristalsis, panesophageal
- pressurisation with >20% of swallows.
- Contractions may be masked by oesophageal pressurization and DCI should not be calculated.

Type III achalasia (spastic achalasia)

- Elevated median IRP (>15 mmHg), no normal peristalsis, premature (spastic)
- contractions with DCI >450 mmHg.s.cm with >20% of swallows

•

177. What will be the appropriate management for Abdominal aortic aneurysm-

- a) Monitor till size reaches 55mm
- b) Immediate surgery
- c) USG monitoring till >70mm asymptomatic
- d) No treatment

Correct Answer - A

Answer- A. Monitor till size reaches 55mm

An asymptomatic abdominal aortic aneurysm in an otherwise fit patient should be considered for repair if >55mm in diameter (measured by ultrasonography).

Regular ultrasonographic assessment is indicated for asymptomatic aneurysms <55 mm in diameter.

75% of aneurysms are suitable for endovascular (minimally invasive) repair, usually via the femoral arteries in the groin.

Ruptured abdominal aortic aneurysm is a surgical emergency.

Symptomatic AAA-

An operation is usually indicated in patients who are otherwise reasonably fit. Pain may be a warning sign of stretching of the aneurysm sac and imminent rupture; surgery should be performed as soon as possible (usually on the next available operating list).

Ref- Bailey and Love, Short practice of surgery, 27th edition published in 2018 Pg 961

178. What is the T stage of a 2.5cm lung carcinoma, not involving the pleura?

a) T1a

b) T2

c) T1b

d) T1c

Correct Answer - D

Ans: D. T1c

TNM 8 th - Primary tumor characteristics	
T_x	Tumor in sputum/bronchial washings but not be assessed in imaging or bronchoscopy
T₀	No evidence of tumor
T_{is}	Carcinoma in situ
T₁	≤ 3 cm surrounded by lung/visceral pleura, not involving main bronchus
T_{1a(mi)}	Minimally invasive carcinoma
T_{1a}	≤ 1 cm
T_{1b}	> 1 to ≤ 2 cm
T_{1c}	> 2 to ≤ 3 cm
T₂	> 3 to ≤ 5 cm or involvement of main bronchus without carina, regardless of distance from carina or invasion visceral pleural or atelectasis or post obstructive pneumonitis extending to hilum
T_{2a}	>3 to ≤4cm
T_{2b}	>4 to ≤5cm
T₃	>5 to ≤7cm in greatest dimension or tumor of any size that involves chest wall, pericardium, phrenic nerve or satellite nodules in the same lobe
T₄	> 7cm in greatest dimension or any tumor with invasion of mediastinum, diaphragm, heart, great vessels, recurrent laryngeal nerve, carina, trachea, oesophagus, spine or separate tumor in different lobe of ipsilateral lung
N₁	Ipsilateral peribronchial and/or hilar nodes and intrapulmonary nodes
2	Ipsilateral mediastinal and/or subcarinal nodes
3	Contralateral mediastinal or hilar; ipsilateral/contralateral scalene/supraclavicular
M₁	Distant metastasis
M_{1a}	Tumor in contralateral lung or pleural/pericardial nodule/malignant effusion
M_{1b}	Single extrathoracic metastasis, including single non-regional lymphnode
M_{1c}	Multiple extrathoracic metastases in one or more organs

Ref- Bailey and Love, Short practice of surgery, 27th edition

179. In, the primary survey which is not included-

a) CECT to look for bleeding

b) Exposure of the whole body

c) ABC

d) Recording BP

Correct Answer - A

Answer – A. CECT to look for bleeding

The primary survey aims to identify and manage the most immediately life-threatening pathologies first and follows cABCDE.

1. c- Exsanguinating external hemorrhage
2. A- airway with cervical spine control
3. B- Breathing & ventilation
4. C- Circulation & hemorrhage
5. D- Disability
6. E- Exposure

An assessment of the hemodynamic status should be made to identify shocked patients: the skin may be pale, cool and sweaty, the pulse rate raised to over 100 per minute and the blood pressure low.

Ref- Bailey and Love, Short practice of surgery, 27th edition published in 2018 Pg 323

180. MC location of gastrinoma in MEN-1 syndrome?

a) Duodenum

b) Jejunum

c) Pancreas

d) Ileum

Correct Answer - A

Answer- A. Duodenum

PETs occur in around 50-60% of MEN 1 patients.

The most common functional tumour is gastrinoma in duodenum followed by insulinoma.

Ref- Bailey and Love, Short practice of surgery, 27th edition published in 2018 Pg 856

181. Patients have precancerous lesions with abdominal swelling and inguinal nodes are seen. On examination, lymphadenopathy was found. The most probable carcinoma related to this condition will be?

a) ca penis

b) CaTestis

c) ca prostate

d) ca bladder

Correct Answer - A

Answer- A. ca penis

Cancer penis spreads to inguinal nodes.

A mass, pruritus or discharge is common. Advanced tumours may cause fecal incontinence by the invasion of the sphincters.

Anal canal tumours are palpable and irregular indurated tender ulceration. Sphincter involvement may be evident.

Ref- Bailey and Love, Short practice of surgery, 27th edition published in 2018 Pg 1371

182. A man under alcohol intoxication had fallen into a manhole and had a perineal injury with swollen scrotum and upper thigh along with blood at meatus. The patient is having difficulty passing urine as well. What will be the injury associated due to this trauma?

a) Bladder rupture

b) Penile fracture

c) Bulbar urethra

d) Membranous urethra

Correct Answer - C

Answer- C. Bulbar urethra

There is a history of a blow to the perineum, usually due to a fall astride injury. The bulbar urethra is crushed upwards onto the pubic bone, typically with significant bruising.

Cycling accidents, loose manhole covers and gymnasium accidents astride the beam account for a number of cases. *C/F*

The signs of a ruptured bulbar urethra are perineal bruising and hematoma, typically with a butterfly distribution. There is usually bleeding from the urethral meatus and retention of urine is also typically present.

Ref- Bailey and Love, Short practice of surgery, 27th edition published in 2018 Pg 1479, 1480

183. Patient with a history of carcinoma bladder presenting with dyspnoea with clinical signs of DVT and tachycardia. The risk for the patient to develop Pulmonary embolism according to WELL's score

a) High

b) Medium

c) Low

d) Cannot comment without d-dimer values

Wells criteria	Score
High	> 6.0
Moderate	2.0 to 6.0
Low	< 2.0
Modified Wells criteria	Score
PE likely	> 4.0
PE unlikely	< or = 4.0

Modified Wells Criteria for DVT	
Variable	Score
Lower limb trauma or surgery or immobilisation in plaster cast	1

Bedridden for >3 days or surgery in the last 4 weeks	1
Tenderness along the line of femoral or popliteal veins	1
Entire limb swollen	1
Calf >3cm larger circumference than the other side	1
10cm below the tibial tuberosity	1
Pitting edema	1
Dilated collateral superficial veins (not varicose veins)	1
Previous DVT	1
Malignancy (including treatment up to 6 months ago)	1
Intravenous drug abuse	3
Alternative diagnosis more likely than DVT	-2

184. After 4 months of renal transplantation, a patient can likely to develop which infection-

a) EBV

b) CMV

c) Candida

d) Histoplasma

Correct Answer - B

Answer- B. CMV

Causes of allograft dysfunction

1. Early

- Primary non-function (irreversible ischaemic damage)
- Delayed function (reversible ischaemic injury)
- Hyperacute and acute rejection
- Arterial or venous thrombosis of the graft vessels
- Drug toxicity (e.g. calcineurin inhibitor toxicity)
- Infection (e.g. cytomegalovirus disease in graft)
- Mechanical obstruction (ureter/common bile duct)

2. Late

- Chronic rejection
- Arterial stenosis
- Recurrence of original disease in the graft (glomerulonephritis, hepatitis C)
- Mechanical obstruction (ureter, common bile duct)

Ref- Bailey and Love, Short practice of surgery, 27th edition published in 2018 Pg 1551

185. The patient is present with fecal peritonitis and during laparotomy, a diverticular perforation is seen. Which stage is classified according to Hinchey's stage?

a) 1

b) 2

c) 3

d) 4

Correct Answer - D

Answer- D. 4

Hinchey classification of complicated diverticulitis.

Grade I Mesenteric or pericolic abscess

Grade II Pelvic abscess

Grade III Purulent peritonitis

Grade IV Faecal peritonitis

**Ref- Bailey and Love, Short practice of surgery, 27th edition
published in 2018 Pg 1274**

186. A young man met with a motorbike accident and had injuries to ileum and jejunum. Therefore the entire ileum and partial jejunum were resected. Which of the following would the patient suffer from

a) Vitamin B12 deficiency

b) Atrophic gastritis

c) Constipation

d) None

Correct Answer - A

Answer- A. Vitamin B12 deficiency

The ileum is the only site of absorption of vitamin B12 and bile salts. Bile salts are essential for the absorption of fats and fat-soluble vitamins.

Following resection of the ileum, the loss of bile salts increases and is not met by an increase in synthesis.

The jejunum is the principal site for digestion and absorption of fluid, electrolytes, iron, folate, fat, protein and carbohydrate, but the absorption of bile salts and vitamin B12 only occurs in the terminal ileum, where there are specific transporters.

Ref- Bailey and Love, Short practice of surgery, 27th edition published in 2018 Pg 283, 1241

187. A patient after a heavy meal comes with epigastric pain. On examination tenderness and rigidity in the upper abdomen. X-ray showing pneumomediastinum. What can be the cause-

- a) Spontaneous esophageal rupture
- b) Penetrating foreign body injury to esophagus
- c) Perforated peptic ulcer
- d) Rupture of emphysematous bulla

Correct Answer - A

Answer- A. Spontaneous esophageal rupture

This is a clinical case of spontaneous esophageal rupture/ Boerhaave's syndrome

The clinical history is usually of severe pain in the chest or upper abdomen after a meal or a bout of drinking.

Mackler's **triad**, which consists of (1) vomiting followed by (2) chest pain and (3) subcutaneous emphysema due to an esophageal rupture.

A chest radiograph is often confirmed with air in the mediastinum, pleura or peritoneum.

Investigations Chest X-ray—shows pneumomdiastinum ('V' sign of Naclerio).

MRI/CT chest.

Total count.

Ref- Bailey and Love, Short practice of surgery, 27th edition

188. Transplantation between identical twins-

a) Isograft

b) Allograft

c) Autograft

d) Xenograft

Correct Answer - A

Answer- A. Isograft

- Graft: It is the transfer of tissue from one area to another without its blood supply or nerve supply.
- Autograft: It is tissue transferred from one location to another on the same patient.
- Isograft: It is tissue transfer between two genetically identical individuals, i.e. between two identical twins.
- Allograft: It is tissue transfer between two genetically different members, e.g. kidney transplantation (Human to human) (Homograft).
- Xenograft: It is tissue transfer from a donor of one species to a recipient of another species (Heterograft).

189. Thoracscore , what is not the component

- a) ASA CLASSIFICATIONS
- b) SURGERY PRIORITIES
- c) Performance status
- d) Expected complications post-surgery

Correct Answer - B

Answer- B. SURGERY PRIORITIES

The Thoracscore is the most widely used model to assess the risk of operative mortality in thoracic patients

Parameters of thoracscore for predicting in-hospital mortality for patients requiring thoracic surgery.

Age (<55, 55-65, >65 years)

Sex

ASA classification (≤ 2 , ≥ 3)

Performance status according to Zubrod scale (≤ 2 , ≥ 3)

Severity of dyspnea according to Medical Research Council Scale (≤ 2 , ≥ 3)

Priority of surgery (elective, urgent/emergency)

Extent of resection (pneumonectomy, other)

Diagnosis (malignant, benign)

Comorbidity score

ASA, American Society of Anesthesiologists.

190. Retrosternal goiter which is true?

- a) All patients should undergo CT chest
- b) All patients require a median sternotomy
- c) it receives blood supply from thoracic vessels
- d) Majority of retrosternal goitres should be operated immediately

Correct Answer - A

Answer- A. All patients should undergo CT chest

Retro sternal goitre tends to arise from the slow growth of a multinodular gland down into the mediastinum.

It gets its blood supply from the mediastinum itself, not from the neck.

Investigations

A chest X-ray shows a soft tissue shadow under the sternum.

A radioactive iodine study is diagnostic.

CT scan/ MRI is useful and all patients should undergo it.

Surgical removal of retrosternal thyroid is done. (TOC)

Commonly it can be removed through an incision in the neck.

Ref- Bailey and Love, Short practice of surgery, 27th edition published in 2018 Pg 810

Sriram Bhat M, SRB's Manual of Surgery, 4th edition published in 2013, Pg 498

191. True for King's Criteria with acute fulminant liver failure except-

a) Age

b) Jaundice <7days

c) Serum bilirubin >17.5 mg/dl

d) INR >3.5

Correct Answer - B

Answer- B. Jaundice <7days

King's College criteria for liver transplantation in AHF.

- APAP-associated AHF-
- pH < 7.3
- or
- INR > 6.5, serum creatinine > 3.4 mg/dl, and grade III-IV encephalopathy
- All other causes of AHF
- INR > 6.5

Or

Three of the following variables:

1. Age > 40 years
2. The cause is non-A, non-B hepatitis or idiosyncratic drug reaction
3. Duration of jaundice before encephalopathy > 7 days
4. INR > 3.5
5. Serum bilirubin > 17.5 mg/dl

APAP, acetaminophen; INR, international normalized ratio.

192. A patient who was posted for elective inguinal hernia surgery has history MI for which he underwent CABG. What will you do in pre operative assessment?

a) History + c/e + routine labs + angiography to look for stent patency

b) History + c/e + routine labs

c) History + c/e + routine labs + stress test

d) History +c/e + routine labs + V/Q scan

Correct Answer - C

Answer- C. History + c/e + routine labs + stress test

In the given scenario the patient had undergone CABG not an angioplasty, so the first option is ruled out.

With routine lab tests, the stress test should be included to check the cardiac function as pre operative assessment

193. History of trauma with a stab injury to the right lower chest with low BP and low pulse rate. It can be improved with IV fluids and after resuscitation in the trauma center patient's BP becomes normal. A chest X-ray showed clear lung fields. What will be the next step-

a) EFAST

b) Keep immediate chest tube

c) CECT abdomen

d) CECT chest

Correct Answer - A

Answer- A. EFAST

Investigations are driven by the cardiovascular status of the patient. In torso trauma, the best and most sensitive modality is a CT scan with intravenous contrast for blunt injury if the patient is stable.

Routine investigation in the emergency department of injury to the chest is based on clinical examination, supplemented by chest radiography.

Ultrasound can be used to differentiate between contusion and the actual presence of blood.

Extended focused assessment with sonar for trauma (eFAST) is becoming the most common investigation.

Ref- Bailey and Love, Short practice of surgery, 27th edition published in 2018 Pg 366, 372

194. In a patient with parathyroid adenoma, how do we confirm the removal of the correct gland after surgery?

a) 50% reduction in PTH after 10mins

b) 50% reduction in PTH after 5mins

c) 25% reduction in PTH after 10mins

d) 25% reduction in PTH after 5mins

Correct Answer - A

Answer- A. 50% reduction in PTH after 10mins

Miami criteria

The IOPTH values at baseline (pre-incision and pre excision) and at 5 and 10 minutes after parathyroidectomy were reviewed according to the Miami criterion (>50% drop from highest baseline IOPTH level at 10 minutes after excision), criterion 1 (>50% drop from pre-incision IOPTH level at 10 minutes), criterion 2 (>50% drop from the highest baseline IOPTH level at 10 minutes and final IOPTH level within the reference range), criterion 3 (>50% drop from the highest baseline IOPTH level at 10 minutes and final IOPTH level less than the pre-incision value), criterion 4 (>50% drop from the highest baseline IOPTH level at 5 minutes), and criterion 5 (>50% drop from pre excision IOPTH level at 10 minutes).

Ref- <https://www.ncbi.nlm.nih.gov/pubmed/16702520>

195. Flap commonly used in breast reconstruction is?

- a) DIEP based on deep inferior epigastric vessels
- b) TRAM based on superior gluteal vessels
- c) Gluteal flap based on thoracodorsal artery
- d) Latissimus dorsi flap based on the inferior epigastric artery

Correct Answer - A

Answer- A. DIEP based on deep inferior epigastric vessels

DIEP flap (based on deep inferior epigastric vessels)

TRAM flap based on It is either superior pedicle based on the superior epigastric vessels or inferior pedicle based on the inferior epigastric vessels.

Latissimus dorsi muscle/myocutaneous flap It is based on the thoracodorsal artery, a branch of the subscapular artery

Superior gluteal flap based on superior gluteal vessels.

Ref- Bailey and Love, Short practice of surgery, 27th edition published in 2018 Pg 879

Sriram Bhat M, SRB's Manual of Surgery, 4th edition published in 2013, Pg 350, 594

196. A 30-year-old man is presented with cramping gluteal pain after walking 500m. Which is the vessel involved during this?

- a) Arterial disease with aortoiliac involvement
- b) Arterial disease with femoral artery involvement
- c) Femoral venous insufficiency
- d) None

Correct Answer - A

Answer- A. Arterial disease with aortoiliac involvement

The muscle group affected by claudication is classically one anatomical level below the level of arterial disease and is usually felt in the calf because the superficial femoral artery is the most commonly affected artery (70% of cases).

Aorto-iliac disease (30% of cases) may cause thigh or buttock claudication. Buttock claudication in association with sexual impotence resulting from arterial insufficiency is eponymously called Leriche's syndrome. It is very rare.

Ref- Bailey and Love, Short practice of surgery, 27th edition published in 2018 Pg 943

197. Which is the most common pancreatic endocrine neoplasm?

a) Insulinoma

b) Gastrinoma

c) VIPoma

d) Glucagonoma

Correct Answer - A

Answer- A. Insulinoma

Insulinoma (70-80%) > Non functional tumours (30- 35%) > gastrinoma (20- 25%)

198. An elderly man with a long-standing mole over the face which is increasing in size and showing irregular borders. What will be the diagnosis?

a) Superficial spreading melanoma

b) Lentigo maligna

c) Acral melanoma

d) Nodular melanoma

Correct Answer - A

Answer- A. Superficial spreading melanoma

Superficial spreading melanoma

- This is the most common presentation (70%) usually arising in a pre-existent naevus after several years of slow change, followed by rapid growth in the preceding months before presentation.

Nodular melanoma (NM) Nodular melanoma accounts for 15% of all MM.

- Typically appear as blue/black papules, 1-2 cm in diameter, and because they lack the horizontal growth phase.

Lentigo maligna melanoma-

- Presents as a slow-growing, variegated brown macule on the face, neck or hands of the elderly.
- **Acral lentiginous melanoma (ALM)** ALM affects the soles of feet and palms of hands.
- It usually presents as a flat, irregular macule in later life.

Ref- Bailey and Love, Short practice of surgery, 27th edition published in 2018 Pg 610

199. Which parameter conclusively rules out malnutrition?

a) Edema

b) Lean body mass

c) Skinfold thickness

d) Normal ECF volume

Correct Answer - B

Ans. B. Lean body mass

Measuring weight and height is the most common way of assessing malnutrition in a given population. Such use of measurements of dimensions of the human body is known as anthropometry.

Anthropometry is a widely used, inexpensive and noninvasive measure of the general nutritional status of an individual or a population group. The three commonly used anthropometric indices are :

- Weight-for-Age {WFA}.
- Length-for-Age or Height-For-Age (HFA).
- Weight-for-Length or Weight-for-Height {WFH}.

PEM reduces growth in children

- Energy expenditure in excess of consumption leads to metabolizing nutrition reserves in the form of stored body fat.
- Lean body mass in the form of muscle and even organ tissue will also be consumed if PEM persists. it serves as a reliable indicator for PEM
- Weight loss accompanies the initial stages of inadequate energy intake but, if prolonged, is followed by wasting, called in its severe clinical form, marasmus.
- In children, PEM delays or permanently stunts growth and increases

200. A 2 years baby with 6.7 kg, Hb%- 6 mg/dl total protein 3mg/dL, low albumin with distended stomach but no proteinuria. What will be the diagnosis?

a) Marasmus

b) Kwashiorkor

c) Indian childhood cirrhosis

d) None

Correct Answer - B

Ans. B. Kwashiorkor

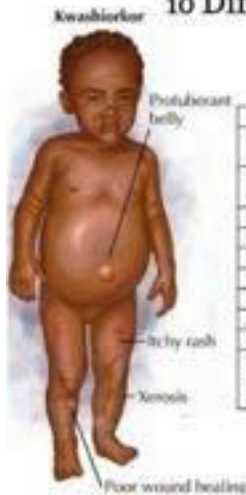Kwashiorkor is a form of severe acute malnutrition (SAM) characterized by edema and apathy.

- Edema is most likely to appear first on the feet and then in the lower legs. It can develop into generalized edema affecting the hands, arms, and face.
- Moon face
- Skin changes include depigmentation of skin, dermatoses, dark, cracked peeling patches (flaky paint dermatosis) with pale skin underneath that is easily infected.
- Hair is sparse, easily pulled out, and may turn reddish.
- Flag sign: alternating bands of hypopigmented and normal pigmented areas on the hair strand
- The liver is often enlarged with fat (fatty Liver).
- The children are miserable and apathetic and often refuse to eat.
- Muscle wasting and growth failure are seen.
- Villous atrophy of small intestine and diarrhea.

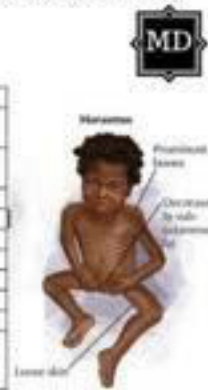10 Differences between Kwashiorkor and Marasmus

www.majordifferences.com

Comparison Table



Kwashiorkor	Marasmus
It develops in children whose diets are deficient of protein.	It is due to deficiency of proteins and calories.
It occurs in children between 6 months and 3 years of age.	It is common in infants under 1 year of age.
Subcutaneous fat is preserved.	Subcutaneous fat is not preserved.
Oedema is present.	Oedema is absent.
Enlarged fatty liver.	No fatty liver.
Ribs are not very prominent.	Ribs become very prominent.
Lethargic.	Alert and irritable.
Muscle wasting mild or absent.	Severe muscle wasting.
Poor appetite.	Voracious feeder.
The person suffering from Kwashiorkor needs adequate amounts of proteins.	The person suffering from Marasmus needs adequate amount of protein, fats and carbohydrates.



Kwashiorkor vs Marasmus

201. In RDS in a child, which cells are found defective?

a) Type 1 pneumocytes

b) Type 2 pneumocytes

c) Bronchial epithelium

d) None

Correct Answer - B

Ans. B. Type 2 pneumocytes

Type I cells form the alveolar wall while the Type II cells synthesize and secrete surfactant DPPC.

The defect in the biosynthesis of Dipalmitoylphosphatidylcholine (DPPC), also known as dipalmitoyl lecithin leads to Respiratory distress syndrome.

Ref. <https://www.ncbi.nlm.nih.gov/pmc/articles/PMC2880575/>

202. Cause of greenish-black stool in a neonate -

a) Meconium

b) Biliverdin

c) Bilirubin

d) Urochrome

Correct Answer - B

Ans. B. Biliverdin

Fetal bowel contents consist of various products of secretion, such as glycerophospholipids from the lung, desquamated fetal cells, lanugo, scalp hair, and vernix. It also contains undigested debris from the swallowed amniotic fluid. The dark greenish-black is caused by pigments, especially biliverdin.

Ref. Williams Obstetrics Ed. 24th Page no. 141

203. A term baby on breastfeeding with bilirubin 14mg/dL which of the following is true?

a) Exchange transfusion

b) Continue to breastfeed

c) Phototherapy

d) None

Correct Answer - B

Ans. B. Continue to breastfeed

Compared with formula-fed newborns, breastfed infants are three to six times more likely to experience moderate jaundice (total serum bilirubin level above 12 mg per dL) or severe jaundice (total serum bilirubin level above 15 mg per dL).

In a breastfed newborn with early-onset hyperbilirubinemia, the frequency of feedings needs to be increased to more than 10 per day. If the infant has a decline in weight gain, delayed stooling, and continued poor caloric intake, formula supplementation may be necessary, but breastfeeding should be continued to maintain breast milk production.

Phototherapy usually not recommended when the total serum bilirubin level is below 15 mg per dL.

Ref: <https://www.aafp.org/afp/2002/0215/p599.html>

204. True hermaphroditism karyotype:

a) 45 X0 streaked gonads

b) 46 XX Ovotestis

c) 47 XY+9

d) 47 XX

Correct Answer - B

Ans. B.46XX Ovotestis

True hermaphrodite or ovotesticular disorder of sexual differentiation (OVO-DSD) is one of the rarest variety of all inter sex anomalies.

In about 90% of cases, patients have 46 XX karyotype.

Rarely, 46 XY/46 XX mosaicism may occur.

205. APGAR score 3 at 1 minute indicates:

a) Mildly depressed

b) Further resuscitation not needed

c) Severely depressed

d) Normal

Correct Answer - C

Ans. C. Severely depressed

APGAR CRITERIA:

	Score of 0	Score of 1	Score of 2	Component of backronym
Skin color	blue or pale all over	blue at extremities body pink (acrocyanosis)	no cyanosis body and extremities pink	Appearance
Pulse rate	absent	< 100 beats per minute	> 100 beats per minute	Pulse
Reflex irritability grimace	no response to stimulation	grimace on suction or aggressive stimulation	cry on stimulation	Grimace
Activity	none	some flexion	flexed arms and legs that resist extension	Activity
Respiratory effort	absent	weak, irregular, gasping	strong, robust cry	Respiration

-
-
-

206. A woman developed pain and crawling sensation on her legs at night. Clinical history of restless leg syndrome. Drug of choice?.

a) Pramipexole

b) Gabapentin

c) Vitamin B12

d) Iron tablets

Correct Answer - A

Ans.a pramipexole

Restless leg syndrome :

- Subjective sensation "creepy-crawly" feeling in the limbs, and irresistible urge to move the legs when at rest or while trying to fall asleep.
- When the individual is lying in bed and relaxing, he or she is disturbed by these sensations.
- Then he or she moves the legs and again tries to fall asleep.
- This cycle sometimes continues for hours and results in profound insomnia.

Treatment:

- The dopaminergic agonists' pramipexole and ropinirole are FDA approved and represent the treatments of choice.

**Ref. Kaplan and Sadock's Synopsis of Psychiatry - 11th Edition
(Page no 559)**

207. History of Arthritis involving 1st MCP joint, other PIP & DIP joints, spares wrist and ankle. What could be the diagnosis

a) Osteoarthritis

b) Rheumatoid arthritis

c) Psoriatic arthritis

d) Gout

Correct Answer - A

Ans: a.Osteoarthritis

>The distal interphalangeal (DIP) joint is actually the most common location on the body for osteoarthritis (OA).

>The frequency of hand arthritis, OA at the DIP joint occurs in approximately 58% of individuals.

>The symptoms of OA at the DIP joint commonly include pain and changes to the size and shape of the joint.

<https://www.3pointproducts.com/blog/health-arthritis-finger-and-toe-conditions/dip-joint-osteoarthritis-how-to-treat-this-common-form-of-arthritis>

208. 12 yr old Child admitted to ICU with blunt trauma and femur fracture- Pao2 60% despite 100%o2 and rebreather mask, CXR shows lung fields clear but the patient remains confused. What is most likely the diagnosis -

a) Pulmonary contusion.

b) Fat embolism syndrome.

c) Hypovolaemic shock.

d) Pulmonary embolism.

Correct Answer - B

Ans: b. Fat embolism.

In this patient, based on the case presentation there is Respiratory System involved as pao2 is 60, and CNS involvement as he is in a confused state.

>So, the diagnosis here is Fat embolism syndrome.

>Embolized fat within capillary beds cause direct tissue damage as well as induce a systemic inflammatory response resulting in pulmonary, cutaneous, neurological, and retinal symptoms.

>Gurd's clinical description of the FES renewed interest in studying this syndrome

<https://www.ncbi.nlm.nih.gov/pmc/articles/PMC3665122/>

209. A 4 yr old child while playing suddenly spun around his elbow from her servant maid's hand and now continuously crying not allowing anyone to touch his elbow. He is keeping his elbow extended .what is most likely the diagnosis -

a) Radial head fracture

b) Pulled elbow

c) supra condylar fracture

d) Elbow dislocation

Correct Answer - B

Ans: b. Pulled elbow

>Pulled elbow, also called nursemaid's elbow, is a radial head subluxation caused by axial traction or a sudden pull of the extended pronated arm, and it is a very common phenomenon.

>In this case of pulled elbow, the child usually avoids moving the affected arm, holding it close to his or her body, without considerable pain, and no obvious swelling or deformity can be seen.

>While a fracture should be excluded, the pulled elbow can usually be identified based on this presentation.

<https://www.ncbi.nlm.nih.gov/pmc/articles/PMC5999240/>

210. A sexually active female with the profuse frothy foul-smelling discharge with intense itching. Strawberry cervix revealed on examination. What will be the diagnosis?

a) Trichomonas vaginalis

b) Bacterial vaginosis

c) Candidiasis

d) None

Correct Answer - A

Answer: a. Trichomonas vaginalis

Trichomonas vaginitis:

Clinical Features:

- There is sudden profuse and offensive vaginal discharge often dating from the last menstruation.
- Irritation and itching of varying degrees within and around the introitus are common.
- There is the presence of urinary symptoms such as dysuria and frequency of micturition.
- There may be history of previous similar attacks

On Examination:

- There is thin, greenish-yellow and frothy offensive discharge per vaginum.
 - The vulva is inflamed with evidences of pruritus.
- Vaginal examination may be painful. The vaginal walls become red and inflamed with multiple punctate hemorrhagic spots. Similar spots

211. 33 yr old female with heavy menstrual bleeding for 6 months comes to the gynaecology OPD. On examination, no abnormality was seen. USG also appeared normal. The patient was tried to be managed on non-hormonal treatment but it failed. What will be the next management step?

a) Hormonal therapy

b) Endometrial sampling

c) Hysterectomy

d) Hysterectomy

Correct Answer - B

Ans. B.Endometrial sampling

Before starting Hormonal therapy endometrial sampling is done as if hormonal therapy precedes sampling the sampling results will be altered.

As already mentioned in question the USG and clinical examination show no abnormality hence the diagnosis can't be made on that so for diagnosis we need to do endometrial sampling and see the hormonal pattern. Then we can proceed with hormonal therapy.

Ref. Dutta Gynaecology ed. 6th page no. 120

212. Postmenopausal women 1st line of drug for osteoporosis is-

a) OCP

b) Bisphosphonates

c) Raloxifene

d) Strontium

Correct Answer - B

Ans. is. B. Bisphosphonates

First line of management of osteoporosis – Bisphosphonates females.

Alendronate, etidronate, pamidronate, and Ibandronate are bisphosphonates which inhibit bone resorption, and are very effective for both osteoporosis prevention and treatment.

Uses:

- First line drugs for treating postmenopausal osteoporosis
- Paget's disease
- Osteolytic bone metastasis.

Raloxifene: It is a selective estrogen receptor modulator which is also useful in management of osteoporosis but it is a hormonal preparation.

213. Prolactin secreted maximum at-

a) 24 hrs after delivery

b) REM

c) 2 hrs running

d) 24 hour after Ovulation

Correct Answer - A

Ans. A. 24 hrs after delivery

Prolactin is maximum 24 hrs after delivery.

Prolactin secretion also increases during strenuous exercise and sleep (NREM).

24 hrs after ovulation estrogen has a negative feedback effect on prolactin which decreases the level of prolactin.

214. All are used for postcoital contraception except-

a) CuT

b) Ru 486

c) High dose estrogen

d) Danazol

Correct Answer - D

Ans. D. Danazol

EMERGENCY CONTRACEPTIVES:

Drug	Dose	PREGNANCY RATE
Levonorgestrel	0.75 mg stat and after 12 hours	0–1
Ethinyl estradiol 50 µg + norgestrel 0.25 mg	2 tab stat and 2 after 12 hours	0–2
Ethinyl estradiol	2.5 mg Bd × 5 days	0–0.6
Mifepristone	100 mg single dose	0–0.6
Copper IUDs (Gold standard)	Insertion within 5 days	0–0.1
(RU 486/Mifepristone) (ulipristal acetate)	30 mg PO	0–1

Ref: DUTTA GYNAECOLOGY ED. 6TH PAGE NO. 492

215. A patient delivered at home with a complete perineal tear came to the hospital after 2 weeks. What management will you prefer?

a) Immediate repair

b) Repair 3 weeks post-delivery

c) Repair 6 weeks post-delivery

d) Repair 3 months post-delivery

Correct Answer - D

Ans. D. Repair 3 months post-delivery

The recent tears should be repaired immediately following the delivery of the placenta. This reduces the chance of infection and minimizes blood loss.

In cases of delay beyond 24 hours, the repair is to be withheld. Antibiotics should be started to prevent infection.

The **complete tear should be repaired after 3 months** if delayed beyond 24 hours.

In case of any doubt to the grade 3rd-degree tear, it is advisable to classify to a higher degree rather than a lower degree.

Ref.Obs Dutta 24th edition Page no. 490

216. In Modern obstetrics, for sensitized Rh-negative mother what should be done to evaluate the condition of the mother?

a) MCA doppler peak systolic volume

b) Fetal blood

c) Amniocentesis

d) Biophysical profile

Correct Answer - A

Ans. A. MCA doppler peak systolic volume

Doppler ultrasound: Serial Doppler study of the middle cerebral artery (MCA)-peak systolic velocity (PSV) is the mainstay to assess fetal anemia. A value >1.5 multiples of the median (MOMs) for the corresponding gestational age, predicts moderate to severe fetal anemia.

This value (between 24 weeks and 35 weeks of gestation), is an indication for cordocentesis and fetal transfusion

Most centers have replaced serial amniocentesis with serial MCA Doppler studies.

Ref. OBstetrics Dutta ed. 8th pg. 391

217. A 7 weeks pregnant lady has 1 accidental exposure to x-ray. Which of the following should be done?

a) Continue pregnancy

b) Terminate pregnancy

c) Chromosome analysis

d) Pre invasive diagnostic testing

Correct Answer - A

Ans. A. Continue pregnancy

Exposure to X-ray has a very low range of rad so in given case scenario Pregnancy will be continued.

Exposure >15 rad during the second and third trimester or >5 rad in the first trimester needs patient counseling. Elective termination of pregnancy may be considered.

Ref. OBS Dutta 8th edition Page no. 740

William's Obs 24th edition Page no. 931 Table no 46-5

**218. A 32-year-old woman complains of amenorrhea since the delivery of a baby 15 months previously, despite the fact that she did not breastfeed her baby. The delivery was complicated by excessive hemorrhage that required a transfusion of 2.5 liters of blood. She has also been fatigued and has gained an additional 4.5Kg since the baby was born. Laboratory data show the following:
Serum LH < 1 IU/L (normal, 4-24 IU/L)
Serum estradiol 5 pg/mL (normal, 20 - 100 pg/mL)
Serum TSH 0.1 mU/L (normal, 0.5 - 5 mU/L)
Serum GH 3 ng/mL (normal, < 5 ng/mL)
Serum ACTH 28 pg/mL (normal, 10 - 50 pg/mL)
Serum prolactin 2 ng/mL (normal, < 20 ng/mL)
Injection of 500 µg of TRH failed to produce the expected rise in both serum TSH and prolactin. Which of the following diagnoses most likely explains the findings in this patient?**

a) Hashimoto's thyroiditis

b) Isolated gonadotropin deficiency

c) Primary amenorrhea

d) Sheehan's syndrome

Correct Answer - D

Ans. D. Sheehan's syndrome

Sheehan's syndrome

- It is hypopituitarism due to ischemic damage to the pituitary resulting from excessive hemorrhage during parturition.
- The pituitary is enlarged during pregnancy; it is more metabolically active, and more susceptible to hypoxemia.
- Furthermore, the blood vessels in the pituitary may be more susceptible to vasospasm because of the high estrogen.
- In about 30% of women who hemorrhage excessively during parturition, some degree of hypopituitarism eventually becomes manifest.
- The symptoms depend on how much of the pituitary is damaged and what cell types are destroyed. The patient described above exhibited persistent amenorrhea after the delivery of her infant.
- This is due to the destruction of pituitary gonadotrophs and diminished secretion of gonadotropins (LH).
- There also appears to have been significant destruction of lactotrophs since TRH injection failed to induce an increase in prolactin.
- Had the women attempted to breastfeed her infant, a failure to lactate mostly likely would have occurred.
- This case is also characterized by secondary hypothyroidism.
- The low TSH and failure to respond to TRH injection are confirmatory.
- Corticotrophs appear to have been spared since plasma ACTH is normal.
- It is not clear whether somatotrophs were damaged.
- Further testing would be needed to see if GH reserve is diminished.

219. Meiosis occurs in

a) Adult ovary

b) Prepubertal testis

c) At birth in ovary

d) All

Correct Answer - A

Ans. is. A. Adult ovary

Meiosis 1 is completed at puberty hence answer is adult ovary

Total number of oocytes at 20 weeks of intrauterine life is about 6–7 million. At birth, the total number of primordial follicles is estimated to be about 2 million. The primary oocytes do not finish the first meiotic division until puberty is reached.

Spermatogenesis occurs at puberty so it cannot happen in prepubertal testis .

**220. DCDA twins, 38wks, first twin breech
mother has BP 140/96, 1+ proteinuria
what's the management**

a) Immediate LSCS

b) Induction at 40 weeks

c) Immediate induction and delivery

d) Induction if signs of preeclampsia

Correct Answer - A

ANS. A. Immediate LSCS

CASE DISCUSSION:

- The patient has mild preeclampsia with BP 140 / 96, so TOP is 37 weeks.
- This patient is 38 weeks so immediate termination of pregnancy is required.
- The first twin is breech so the mode of delivery is LSCS hence the answer is A.

INDICATIONS OF CESAREAN SECTION:

The indications are broadly divided into:

Obstetric

- Placenta previa
- **Preeclampsia**
- Previous cesarean section
- Cord prolapse of the first baby
- Abnormal uterine contractions
- Contracted pelvis.

For twins:

- Both the fetuses or even the first fetus with noncephalic (breech or

-
-
-
-

221. A 36-week old pregnant lady with previous twin delivery. What is the Ovarian score?

a) G2P1

b) G2P2

c) G3P2

d) G3P3

Correct Answer - A

ANS. A.G2P1

Gravida includes all confirmed pregnancies. Each pregnancy is only counted one time, even if the pregnancy was multiple gestations, such as twins or triplets

Parity reflects the total number of births after 20 weeks, not the total number of infants born.

Ref.OBS Dutta 8th ed Page no. 107

222. Misoprostol used in the induction of labour is an analogue of which of the following type of prostaglandin?

a) PG E1

b) PG E2

c) PG I2

d) PG F2alpha

Correct Answer - A

Correct Ans: A. PG E1

Misoprostol is a methyl ester of PGE1.

Indications of Misoprostol:

- It is used for cervical ripening.
- Transvaginally it is used for induction of labour.

Uses of Prostaglandins in Obstetrics:

- Induction of abortion
- Termination of molar pregnancy
- Induction of labour
- Cervical ripening prior to induction of labour
- Acceleration of labour
- Management of atonic postpartum hemorrhage
- Medical management of tubal ectopic pregnancy

223. In early pregnancy clinical signs of feeling the cervix and the body of bulky uterus separated because of softened isthmus at 6 - 8 weeks of gestation :

a) Goodell's sign

b) Chadwick's sign

c) Piskacek's sign

d) Hegar's sign

Correct Answer - D

Correct Ans: D. Hegar's sign

At 6 to 8 weeks menstrual age, the firm cervix contrasts with the now softer fundus and the compressible interposed softened isthmus

—*Hegar sign*

224. 13 yr old child visit gynaecology OPD with a complaint of not attaining menarche with karyotype 46XX. On examination, clitoromegaly is seen. Which enzyme is most likely to be deficient in the above condition?

a) 21 alpha-hydroxylase

b) 11 beta-hydroxylase

c) 17 alpha-hydroxylase

d) 3 beta-hydroxysteroid dehydrogenase

Correct Answer - A

Ans. A. 21 alpha-hydroxylase

The condition described above represents the Congenital adrenal hyperplasia.

"More than 90% of CAH cases are caused by 21-hydroxylase deficiency"

Congenital adrenal hyperplasia:

It is due to an inborn error of adrenal steroid metabolism, commonly due to 21-hydroxylase (95%) and rarely due to 11-hydroxylase or 3 β hydroxysteroid dehydrogenase deficiency.

Clinical presentation

- An ambiguity of sex at birth
- Hirsutism and amenorrhea may be the presenting features around puberty in a milder form.

The karyotype is 46, XX.

Ref. Dutta Gynaecology ed. 6th page no. 440

225. A mother brought her 16-year-old daughter to Gynaecology OPD with a complaint of not attending menarche. She gives H/O cyclic abdominal pain. On further examination midline, abdominal swelling seen. Per rectal examination reveals a bulging mass in the vagina. Which of the following can be most commonly seen?

a) Imperforate hymen

b) Transvaginal septum

c) Vaginal agenesis

d) MRKH

Correct Answer - A

Ans. A. Imperforate hymen

According to the clinical case, patients suffer from primary amenorrhea and cryptomenorrhea(cyclic abdominal pain).

The girl is aged about 14–16 years.

- The chief complaints are periodic lower abdominal pain, which may be continuous, primary amenorrhea and urinary symptoms, such as frequency, dysuria or even retention of urine.
- In fact, in significant cases, the presenting feature may be the retention of urine. The cause of retention is due to the elongation of the urethra.
- An abdominal examination reveals a suprapubic swelling, which may

•

226. Which of the following is not an estrogen-dependent pubertal change?

a) Hair growth

b) Menstruation

c) Vaginal Cornification

d) Cervical mucus

Correct Answer - B

Ans. B. Menstruation

Pubarche or development of axillary and pubic hair is due to testosterone (in both the sexes).

Puberty in females :

- Involves the beginning of menstrual cycles (menarche), breast development (thelarche), and an increase in adrenal androgen secretion (adrenarche).
- Estradiol induces the development of secondary sex characteristics, including the breasts and reproductive tract, and increased fat in the hips.
- Estrogens also regulate the growth spurt at puberty, vaginal cornification, and cervical mucus production, induce closure of the epiphyses, have a positive effect in maintaining bone formation, and can antagonize the degrading actions of parathyroid hormone on bone.

Reference: Rhoades and Tanner's Medical Physiology, 2nd edition
(Page no: 680)

227. A 22-year-old primigravida visits ANC OPD with 20 weeks POG. On examination uterine height reveals a 16-week size. USG shows reduced liquor. What will be the diagnosis?

a) Renal agenesis

b) Fetal anemia

c) Barter's syndrome

d) Liddle syndrome

Correct Answer - A

Ans. A. Renal agenesis

The question states reduced liquor that means oligohydramnios is seen.

Oligohydramnios is defined as an amniotic fluid index of 5 cm or less.

It is almost always present when there is either obstruction of the fetal urinary tract or renal agenesis.

Williams Obstetrics ed 24th page 237

228. Most common site for Fertilization is-

a) Ampulla

b) Isthmus

c) Intramural

d) Fimbriae

Correct Answer - A

Ans. A. Ampulla

Fertilization is the process of fusion of the spermatozoon with the mature ovum.

It begins with sperm egg collision and ends with the production of a mononucleated single cell called the zygote.

Its objectives are:

- To initiate the embryonic development of the egg and
- To restore the chromosome number of the species.

Almost always, fertilization occurs in the ampullary part of the uterine tube.

Reference: Dutta Obstetrics ed. 8th Page no 23

229. Distension media used for hysteroscopy with bipolar cautery?

a) Glycine

b) NS

c) Co2

d) Dextran 70

Correct Answer - B

Ans. B. NS

The distending media commonly used in hysteroscopy is normal saline

—The uterine cavity is distended with a media to separate the uterine walls and to have a panoramic view. The media used could be either a gas or a liquid.

Carbon dioxide (CO₂)—is commonly used for diagnostic purposes. It is soluble in blood and is safe.

Hysteroflator provides a gas flow rate of a maximum of 100 mL per minute and a maximum pressure of 100 mm Hg.

Liquid media is used for operative procedures.

Normal saline can be used is suitable for bipolar cautery but not suitable for monopolar electrosurgery. Constant flow is to be maintained to flush the operative area.

Ref. Dutta Gynaecology ed. 6th page no. 620, 624

230. Best treatment option for septate uterus-

a) Tompkins Metroplasty

b) Jones metroplasty

c) Strassmann metroplasty

d) Transcervical hysteroscopic resection of the septum

Correct Answer - D

Ans. D. Transcervical hysteroscopic resection of the septum

Hysteroscopic metroplasty is more commonly done.

Resection of the septum can be done either by a resectoscope or by laser.

Advantages are:

High success rate (80–89%),

Short hospital stay

Reduced postoperative morbidity (infection or adhesions)

Subsequent chance of vaginal delivery is high compared to abdominal metroplasty where the cesarean section is mandatory.

Other methods:

Abdominal metroplasty could be done either by excising the septum (Strassman, Jones, and Jones) or by incising the septum (Tompkins).

Ref. Dutta Gynaecology ed. 6th page no. 47

231. A pregnant female had Meconium stained liquor and underwent emergency LSCS. A few days later her condition deteriorated. USG showed edematous bowels. What's the cause?

a) Meconium peritonitis

b) Paralytic ileus

c) Adhesive intestinal obstruction

d) Intra-abdominal abscess

Correct Answer - B

Ans.B. Paralytic ileus

POSTOPERATIVE COMPLICATIONS OF LSCS:

Intestinal obstruction: The obstruction may be mechanical due to adhesions or bands, or paralytic ileus following peritonitis.

Paralytic ileus is an adynamic obstruction in which there is a failure of transmission of peristaltic waves

Clinical features :

The resultant stasis leads to the following:

- Accumulation of fluid and gas in the bowel
- With associated distension: marked and tympanitic
- Vomiting (effortless)
- Absence of bowel sounds
- Absolute constipation

Dutta obstetrics ed. 8th Page no. 678

Bailey & Love's Short Practice of Surgery - 27th Edition (Page no 1297)

**232. 18-year-old girl presents with 6 months of amenorrhea with h/o low-grade fever, weight loss, pain abdomen, generalized weaknesses. On PR examination, palpable left-sided pelvic mass felt...
Diagnosis is**

a) Fibroid with degeneration

b) TB pelvis with Tubo ovarian mass

c) Ectopic pregnancy

d) Granulosa cell tumour

Correct Answer - B

Ans.B.TB pelvis with Tubo ovarian mass

The tubercles burst to pour the caseous material inside the lumen producing tubercular pyosalpinx, which may adhere to the ovaries and the surrounding structures.

Often the infection spreads outwards producing peri salpingitis with exudation, causing dense adhesions with the surrounding structures tubercular tubo-ovarian mass.

Clinical diagnostic features:

- Weakness, low-grade fever, anorexia, anemia or night sweats may be present.
- Infertility: It may be primary or secondary
- Chronic pelvic pain
- Vaginal discharge— postcoital bleeding or a blood-stained discharge.
- Constitutional symptoms such as loss of weight, malaise, anorexia,

•

•

233. A Child is born, covered with a thick membranous coat, what could be the possible diagnosis?

a) Lamellar ichthyosis

b) X-linked ichthyosis

c) Ichthyosis Vulgaris

d) Ichthyosis acquista

Correct Answer - A

Answer- a. Lamellar ichthyosis

Explanation- Ichthyosis is one of the most common genodermatoses. It is characterized by dry (xerotic) scaly skin all over the body. Scales are dull-brown-black.

The basic defect is an impairment in the barrier function of skin and inability to maintain moisture. Collodion baby is the term used to denote the newborn baby with ichthyosis; the newborn baby is encased in a thick, shiny membrane coat called collodion and is seen in Lamellar ichthyosis

Ref- Arvind Arora skin, 6th edition, page no 203

234. Mouth to mouth respiration provides what percentage of oxygen ?

a) 10%

b) 16%

c) 21%

d) 100%

Correct Answer - B

Ans. B. 16%

Mouth to mouth breathing provides 0.8 to 1.2 liters of exhaled air per breath and 16% of oxygen which is enough to sustain life.

The use of Ambu bag and room air provides 21% O₂.

The American Heart Association recommends tidal volumes of 700 to 1000 mL during mouth-to-mouth ventilation, but smaller tidal volumes of 500 mL may be of advantage to decrease the likelihood of stomach inflation, as mouth-to-mouth ventilation gas contains only 17% oxygen, but 4% carbon dioxide.

235. Cancer patient undergoes radiotherapy, pick the true statement for radiosensitivity of tissues?

- a) Rapidly dividing cells are resistant to radiation
- b) GI mucosa is one of the most radioresistant tissues in the body
- c) The intensity of radiation is inversely proportional to the square of distance from the source
- d) Small blood vessels are least resistant to radiation

Correct Answer - C

Answer- C- The intensity of radiation is inversely proportional to the square of distance from the source

The **inverse square law** describes the principle of dose reduction as the distance from the source increases.

The dose is proportional to the inverse of the square of the radius. Thus if you double the distance you reduce the dose by a factor of four.

Ref- 1. Shafiei SA, Hasanzadeh H, Shafiei SA. A simple calculation method for determination of equivalent square field. J Med Phys. 2012;37 (2): 107-11. [DOI:10.4103/0971-6203.94746](https://doi.org/10.4103/0971-6203.94746) - [Free text at PubMed](#) - [Pubmed citation](#)

236. Most common DRUG causing dependence?

a) Cannabis

b) Cocaine

c) Heroin

d) Amphetamine

Correct Answer - A

ANS - A.Cannabis

Cannabis- 9 million users,192 million users(Acc. To WHO Drug report 2018)

Heroin (opioid derivative) -2.5 lakh users

It is estimated that 275 million people used illicit drugs, such as cannabis, amphetamines, opioids, and cocaine, in 2016 which translates into an annual prevalence of illicit drug use of 5.6%.

Cannabis is most used with 192 million users. Some 31 million people who use drugs suffer from drug use disorders.-(WHO Drug report 2018)

Ref: ARVIND ARORA review of psychiatry p:64, WHO Drug report(2018)

237. MBBS student she was choking with dyspnea, chest tightness, anxiety and an impending sense of doom on examination all systemic conditions were found normal, then she went to psychiatry. What is the probable diagnosis of the condition?

a) Panic disorder

b) Depression

c) Epilepsy

d) Asthma

Correct Answer - A

ANS - A. Panic disorder

Panic disorder-severe anxiety with choking, chest pain and palpitations.

Depression- low mood and lost interest in activities

Epilepsy-neurological disorder with whole-body fatigue and muscle spasms

An asthma-respiratory disorder associated with symptoms of cough, wheezing, etc

Ref: ARVIND ARORA review of psychiatry p:131

238. A patient with depression was given Imipramine for 2 weeks. Relatives noticed increased excitement, colourful clothes, increased talking. What is the next step in management?

- a) Antipsychotic with Imipramine continued
- b) Discontinue Imipramine and start Valproate
- c) Continue Imipramine alone
- d) Manage with Valproate alone

Correct Answer - A

ANS-A. Antipsychotic with Imipramine continued

The condition from which the patient above is suffering is a bipolar disorder which includes both depression and mania.

So in order to treat both antidepressant i.e imipramine is continued along with an antipsychotic such as phenothiazines, thioxanthenes, etc.

Antipsychotic or valproate alone cannot reduce the depression and Imipramine alone cannot reduce the mania.

Ref: ARVIND ARORA review of psychiatry p.no:111

239. A Patient falls down often with behavioral change and enuresis. What is the condition associated with him?

a) Frontotemporal dementia

b) Normal pressure hydrocephalus

c) Parkinson's disease

d) Alzheimer's disease

Correct Answer - B

Ans- B. Normal pressure hydrocephalus

Frontotemporal dementia - Associated with poor behavioral control, decision making, and language.

Normal-pressure hydrocephalus - Associated with gait disturbance, behavioural change, enuresis, and dementia.

Parkinson's disease - Associated with tremor and muscular stiffness

Alzheimer's disease-Associated mainly with memory loss and confusion

Ref: Normal Pressure Hydrocephalus By Michael J. Fritsch, Uwe Kehler, Ullrich Meier P .16; Oxford textbook of neurological surgery by Adel Helmy P.94

240. A Patient with depressive symptoms for 6 months and associated with auditory hallucinations for 2 weeks. What is the probable diagnosis of the condition?

a) Psychotic depression

b) Schizoaffective disorder

c) Mania depressive illness

d) Schizophrenia

Correct Answer - A

Ans- A. Psychotic depression

Psychotic depression- Depression along with psychotic symptoms such as hallucinations, delusions, etc.

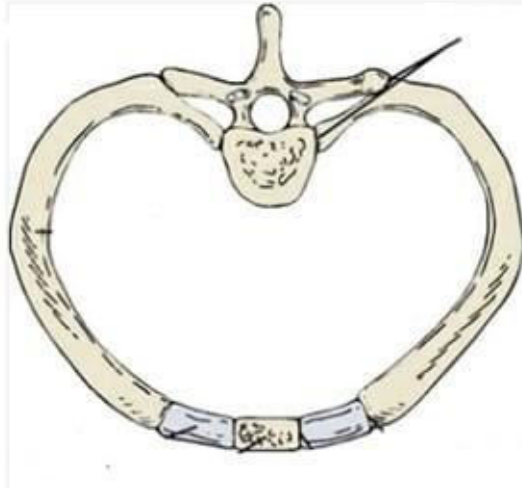
Schizoaffective disorder-Symptoms of schizophrenia and mood disturbances occur together.

Mania depressive illness - Mania depression along with psychotic symptoms.

Schizophrenia includes all the symptoms of schizophrenia

Ref: Arvind Arora review of Psychiatry page. 103

241. Identify the type of joint in the given picture



a) Syndesmosis

b) Synarthrosis

c) Synovial joint

d) Symphysis

Correct Answer - C

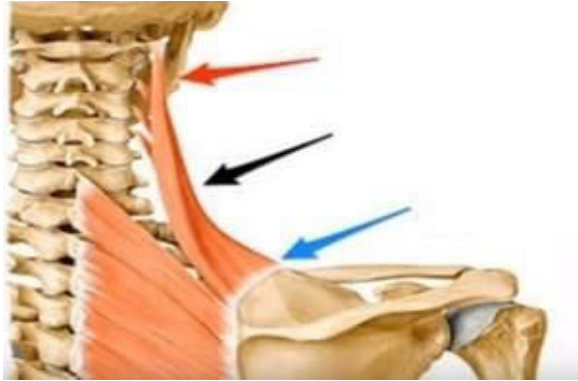
Ans: C synovial joint

The marked structure is a joint between the transverse process of vertebra and ribs - a costotransverse joint.

Interchondral, Sternocostal, Costovertebral, and Costotransverse are all plane types of synovial joints.

BDC, 7th edition, volume 1, pg 234.

242. Identify the muscle. What is its nerve supply



a) Dorsal scapular nerve

b) Thoracodorsal nerve

c) Spinal accessory nerve

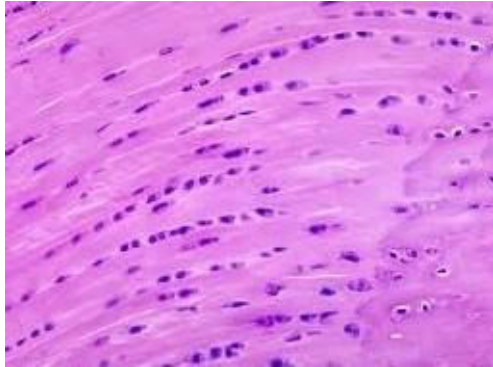
d) Suprascapular nerve

Correct Answer - A

Ans: A. Dorsal scapular nerve

Marked muscle is levator scapulae. It is supplied by C3, C4, and C5 (dorsal scapular nerve)

243. Identify the cartilage



a) Hyaline cartilage

b) Elastic cartilage

c) Articular cartilage

d) Fibrocartilage

Correct Answer - D

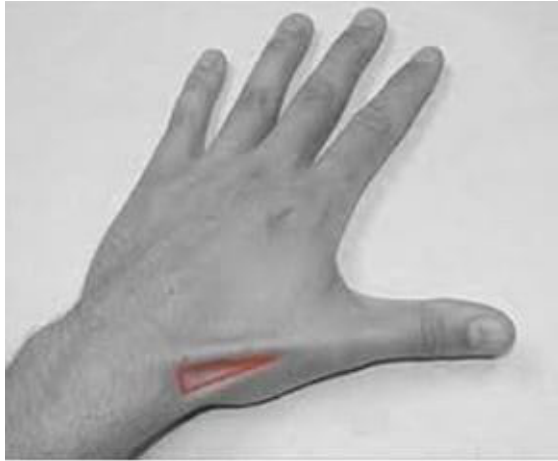Ans:D. Fibrocartilage

Fibrocartilage

Fibrocartilage is characterized by a large amount of irregular and dense bundles of collagen fibers in the matrix. It consists of alternating layers of cartilage matrix and thick dense layers of type I collagen fibers.

**Ref. Inderbir Singh's Textbook of Human Histology- 8th Edition
(Page nos 56-59)**

244. Identify the boundaries of the anatomical structure in the image



a) Extensor pollicis longus

b) Abductor pollicis longus

c) Styloid process of the radius

d) All of the above

Correct Answer - D

Ans: D. All of the above

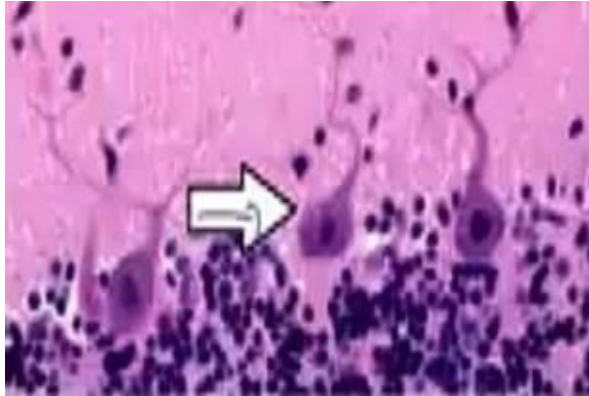The marked structure is the anatomical snuff box.

Boundaries are:

- The medial border (ulnar side) of the snuffbox is the tendon of the extensor pollicis longus.
- The lateral border (radial side) is a pair of parallel and intimate tendons of the extensor pollicis brevis and the abductor pollicis longus.
- The proximal border is formed by the styloid process of the radius
- The distal border is formed by the approximate apex of the schematic snuffbox isosceles triangle.

•

245. Identify the cell type marked in the cerebellum?



a) Basket cells

b) Granule cells

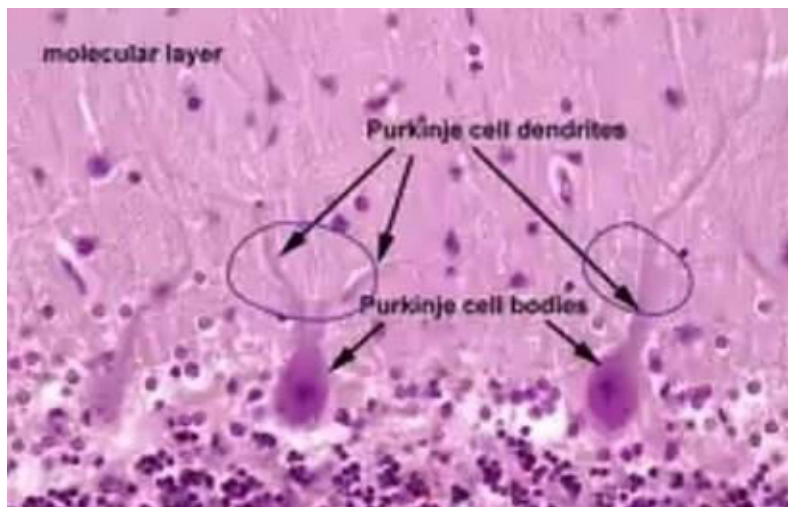
c) Golgi cells

d) Purkinje cells

Correct Answer - D

Ans: D. Purkinje cells

Explanation:



-
-
-
-

246. Identify the sleep wave marked in the EEG during the sleep-wake cycle?



a) Stage 1 sleep

b) REM sleep

c) Stage 2 sleep

d) Stage 3 sleep

Correct Answer - B

Ans: B. REM sleep

Explanation:

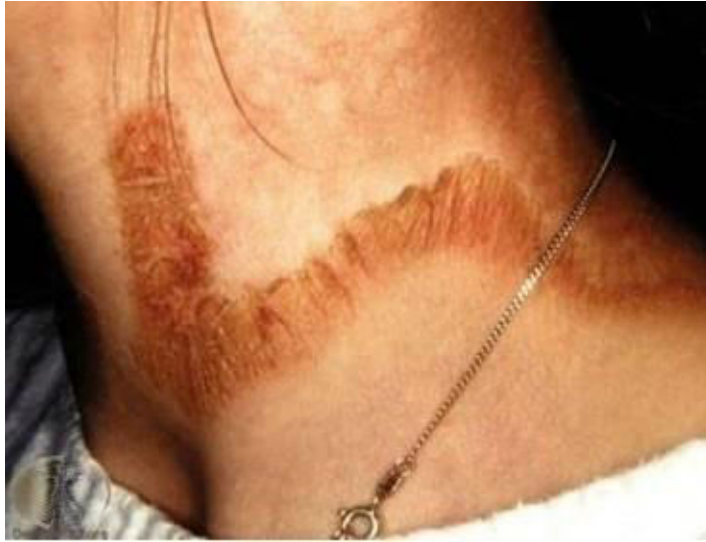REM/Paradoxical Sleep:

- Due to the "presence of rapid eye movement" recorded on electrooculogram.
- Has paradoxical elevation of brain activity, metabolism & physiological activity.
- "High-amplitude slow waves" replaced by "rapid, low voltage activity & beta wave" -
- During stage 3 & 4 REM sleep.

Features of REM sleep:

-
-
-
-

247. Casal's necklace is seen in deficiency of:



a) Vitamin A deficiency

b) Niacin

c) Iron deficiency anemia

d) Vitamin B12 deficiency

Correct Answer - B

Ans: B. Niacin

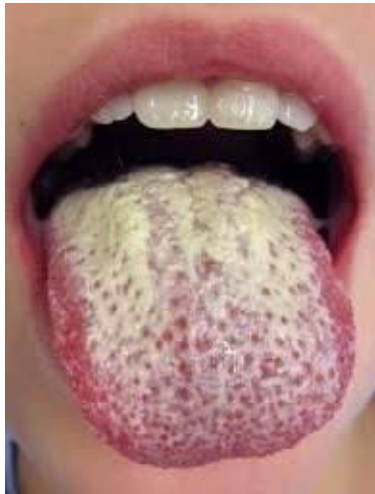The deficiency of niacin leads to the clinical condition called pellagra. Pellagra is an Italian word, meaning "rough skin". Pellagra is caused by the deficiency of Tryptophan as well as Niacin. Pellagra is seen more in women; this may be because tryptophan metabolism is inhibited by estrogen metabolites.

The symptoms of pellagra are:

- **Dermatitis:** In the early stages, bright red erythema occurs, especially in the feet, ankles, and face. Increased pigmentation around the neck is known as Casal's necklace. The dermatitis is

•
•
•

248. An Hiv positive patient with a CD4 COUNT OF 300/Cumm presents with mucosal lesions in the mouth as shown in the figure. on microscopy budding yeasts and pseudohyphae are seen. A most probable diagnosis is?



a) Candidiasis

b) Hairy leukoplakia

c) Lichen planus

d) Diphtheria

Correct Answer - A

Correct Ans: A. Candidiasis

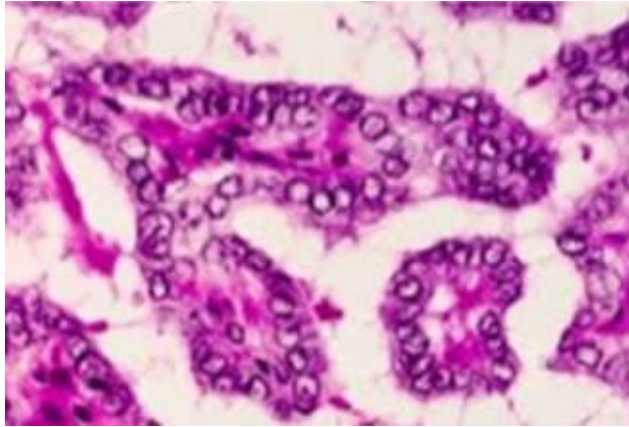
Most common opportunistic infection in HIV is candidiasis

Candidiasis is a fungal infection due to any type of Candida.

When it affects the mouth, it is commonly called thrush.

Signs and symptoms include white patches on the tongue or other

249. A 25-Year-old male presented with a 2cm thyroid nodule. A thyroidectomy was done. The histology picture is given below.what could be the diagnosis



a) Papillary carcinoma thyroid

b) Follicular adenoma

c) Graves disease

d) Adenomatous goitre

Correct Answer - A

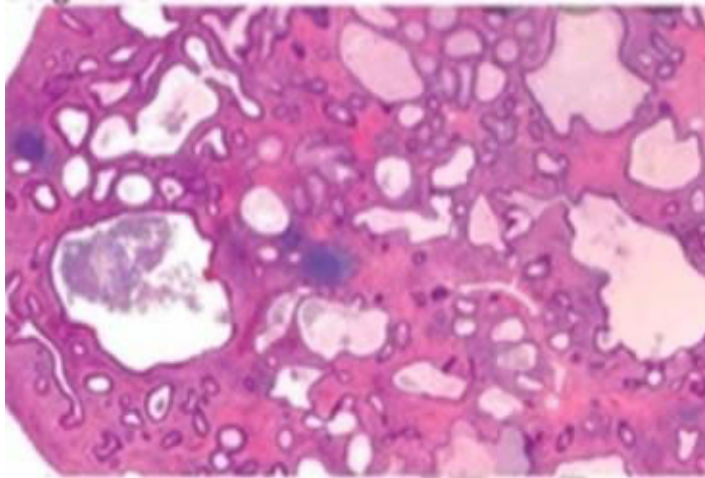
Ans: A. Papillary carcinoma thyroid

Papillary carcinomas may manifest as solitary or multifocal lesions within the thyroid. In some cases, they may be well-circumscribed and even encapsulated; in other instances, they infiltrate the adjacent parenchyma with ill-defined margins.

The lesions may contain areas of fibrosis and calcification and often are cystic. On cut surface, they may appear granular and sometimes contain grossly discernible papillary foci.

The definitive diagnosis of papillary carcinoma can be made only

250. A 5-year-old child presented with a history of blood in the stools. On examination, there was a polypoid mass in the rectum, a biopsy of which showed as below. A most probable diagnosis is?



a) Villous adenoma

b) Juvenile polyp

c) Vascular malformation

d) Serrated adenoma

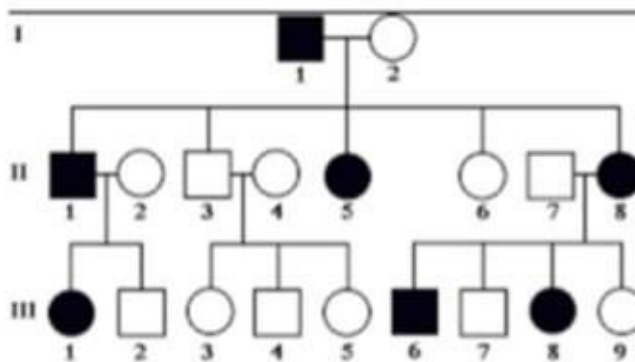
Correct Answer - B

Ans: B. Juvenile polyp

The histological picture of juvenile polyps. It consists of pedunculated, smooth-surfaced, reddish lesions that are less than 3 cm in diameter and display characteristic cystic spaces on cut sections.

Microscopic examination shows the spaces to be dilated glands

251. 25-year-old man presents for a routine physical examination. The patient is tall and on examination, he was found to have an early diastolic murmur. His family pedigree is given below. Which of the following is the mode of inheritance by which the disease is likely to be transmitted?



a) AD

b) AR

c) XLR

d) XLD

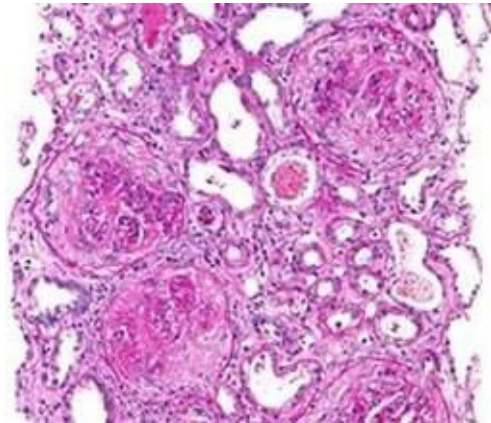
Correct Answer - A

Ans: A. AD

Autosomal Dominant (AD) Inheritance Diseases

- Mutated genes can express themselves in a heterozygous state.
- Usually, it causes a defect in the synthesis of structural Q or non-

252. A 51-year-old person came with a complaint of hematuria. On examination, he was normotensive and had pedal edema. Investigations revealed the patient had no glucosuria and had a creatinine value of 9mg%. Renal biopsy is as shown below which of the following investigations one should do to identify the etiology of the disease?



a) ANA

b) ANTI GBM antibodies

c) HIV RNA

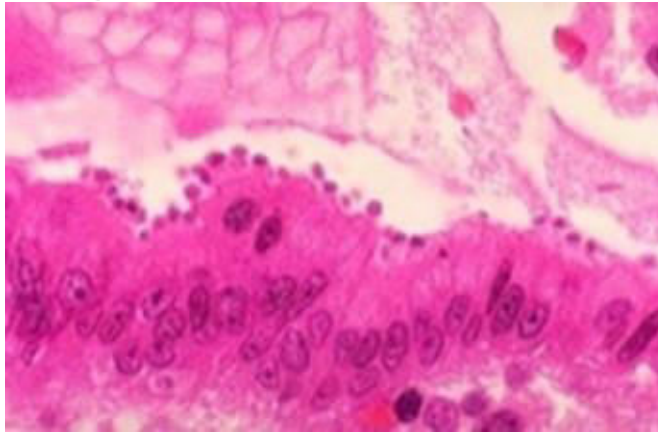
d) Urine immunoelectrophoresis

Correct Answer - B

Ans: B. ANTI GBM antibodies

Kidney biopsy: Immunofluorescence demonstrated linear staining

253. A 35-year-old heterosexual patient diagnosed with HIV had a history of chronic watery diarrhea. A colonoscopic biopsy is shown below. A most probable diagnosis is?



a) Giardia

b) CMV

c) Microspora

d) Cryptosporidium

Correct Answer - D

Ans: D. Cryptosporidium

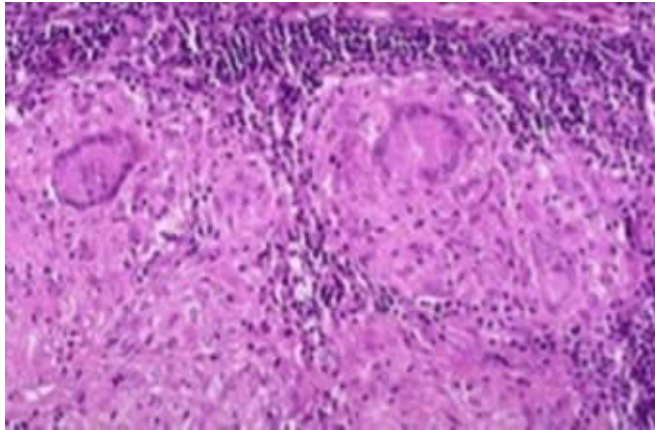
Disease caused by infection with *Cryptosporidium* species, a protozoal parasite

Traditionally considered a coccidian parasite, but recent evidence suggests it may be a [gregarine](#) parasite

Infection is most common in the terminal ileum and proximal colon

The disease also occurs in the proximal small intestine, distal colon, gallbladder, bile ducts, and pancreas

254. An 11-year boy presented with cough for 15 days on examination he was found to have cervical lymphadenopathy. lymph node examination showed below finding what could be the diagnosis



a) Leprosy

b) Sarcoidosis

c) TB

d) Syphilis

Correct Answer - C

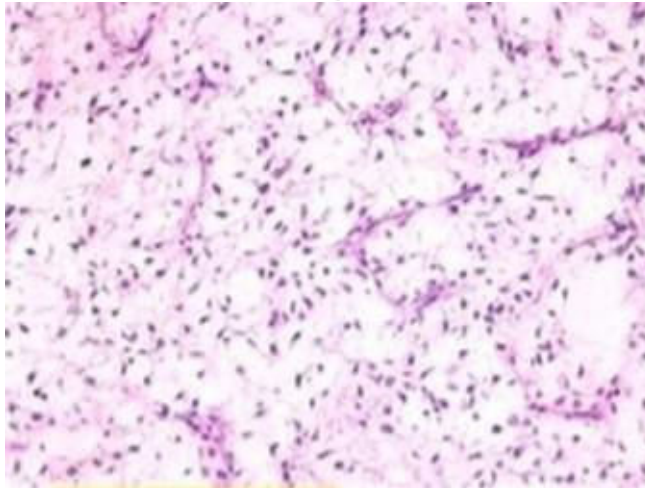
Ans: C. TB

Histological picture shown above is of tuberculosis

Tuberculosis is a communicable chronic granulomatous disease caused by *Mycobacterium tuberculosis*. It usually involves the lungs but may affect any organ or tissue in the body.

Typically, the centers of tuberculous granulomas undergo caseous necrosis. histologic xamination, sites of active involvement are

255. A 40year old person presented with 10*8 swelling in a retroperitoneal,biopsy from the lesion is as shown below. Molecular analysis demonstrated t(12,16). A most probable diagnosis is



a) Myxoid liposarcoma

b) Lipoma

c) Synovial sarcoma

d) Pleomorphic sarcoma

Correct Answer - A

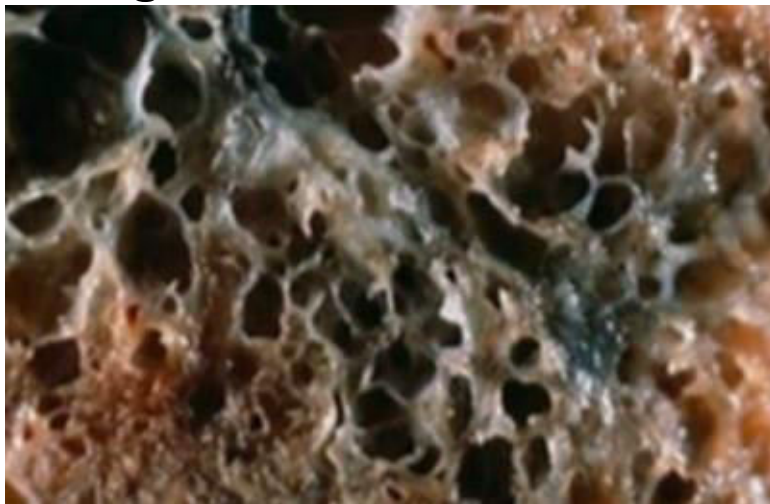Ans: A. Myxoid liposarcoma

Myxoid liposarcoma is the most common histologic type.

It is composed of monomorphic, fusiform or stellate cells representing primitive mesenchymal cells, lying dispersed in mucopolysaccharide-rich ground substance.

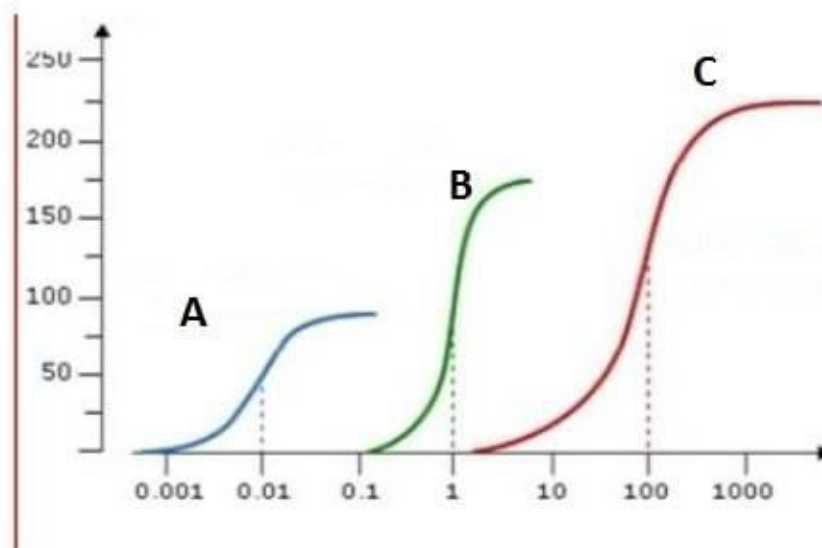
Occasional tumour giant cells may be present. The prominent

256. 47. 35-year-old woman with a long history of dyspnea, chronic cough, sputum production, and wheezing dies of respiratory failure following a bout of lobar pneumonia. She was not a smoker or an alcoholic. The lung autopsy is shown in the image. Which of the following underlying condition was most likely associated with the pathologic changes shown here?



- a) Mutation in dynein arms
- b) Cystic fibrosis
- c) Alpha 1 antitrypsin deficiency
- d) Antibodies against type 4 collagen

**257. Graph showing three drugs A, B & C.
Which of the following drugs shown in
the graph below has the highest
potency?**



a) Drug A

b) Drug B

c) Drug C

d) Both Drug A & B

Correct Answer - A

Ans: A. Drug A

The line on the left is more potent.

Drug A is more potent.

Drug Potency:

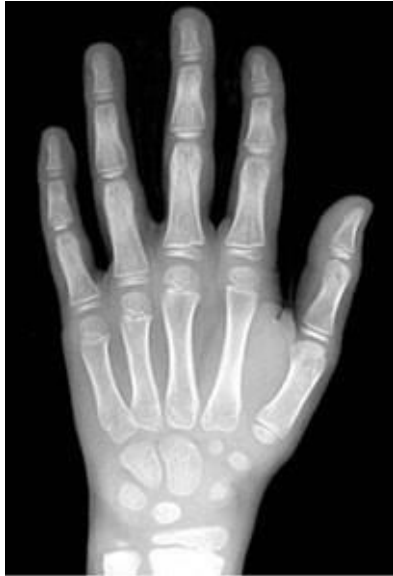- The position of DRC on the dose axis is the index of drug potency which refers to the amount of drug needed to produce a certain

•

•

•

258. In the following X-ray of the wrist, what is the exact age-



a) 2 yrs

b) 8yrs

c) 6yrs

d) 9 yrs

Correct Answer - C

Answer- C- 6 yrs

Assessments of skeletal maturity in pre-pubertal children are primarily based on the epiphyseal size of the phalanges as they relate to the adjacent metaphyses.

During this stage of development, the ossification centers for the epiphysis increase in width and thickness, and eventually assume a transverse diameter as wide as the metaphysis

More weight is given to the size of the epiphysis in the distal

phalanges than to that in the middle phalanges, and even less to that in the proximal phalanges.

http://www.chospab.es/biblioteca/DOCUMENTOS/Atlas_of_Hand_Bo_n

259. Identify the phenomena



a) Electric Burn

b) Crocodile Burn

c) Scalds

d) Putrefaction

Correct Answer - D

Answer- D- Putrefaction

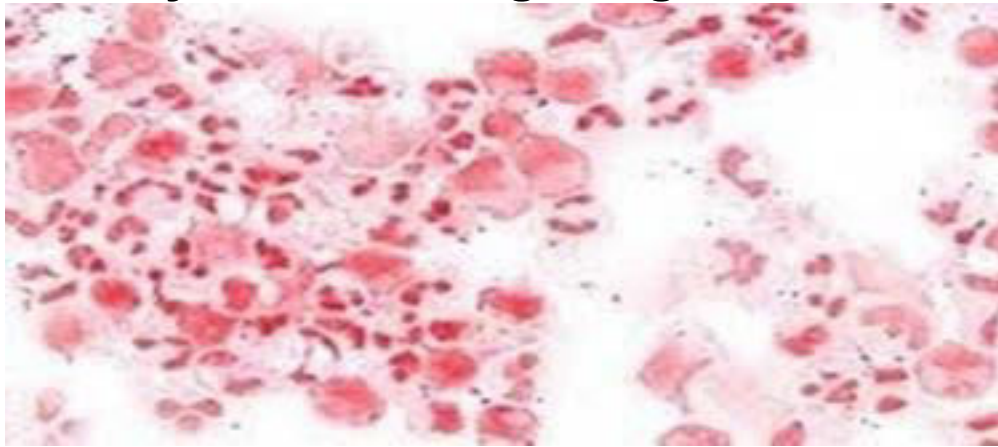
Putrefaction is the decomposition of the body carried out by the microbial action. After cessation of hemostasis, the natural flora of the body migrates from the gut to the blood vessels and spreads all over the body.

External micro-organisms enter the body through the alimentary canal, respiratory tract, and open wounds. In the absence of body defenses/immune mechanisms, the microbes keep growing, as they feed upon the proteins and carbohydrates of the blood and body parts.

The principal bacterial agent causing putrefaction is the gram-positive, anaerobic, and rod-shaped *Clostridium welchii*.

It releases lecithinase, which causes hydrolysis of lecithin present in the blood cells, causing their lysis. Putrefaction begins within an

260. Identify the following Image



a) Neisseria meningitidis

b) Neisseria cinerea

c) Neisseria gonorrhoeae

d) Neisseria polysaccharea

Correct Answer - A

Answer-A- Neisseria meningitides

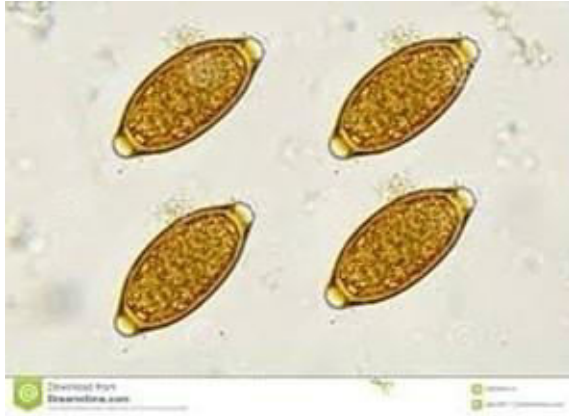Neisseria meningitidis often referred to as meningococcus, is a Gram-negative bacterium that can cause meningitis and other forms of meningococcal disease such as meningococcemia, life-threatening sepsis.

N.meningitidis is a gram-negative β proteobacterium and member of the bacterial family of Neisseriaceae.

N. meningitidis is a fastidious bacteria, dying within hours on inanimate surfaces, and is either an encapsulated or unencapsulated, aerobic diplococcus with a "kidney" or "coffee-bean" shape.

Jawetz 27/e-pg-287;

261. Identify the Image



a) *Trichuris trichiura*

b) *Ancylostoma duodenale*

c) *Paragonimus*

d) *Strongyloides*

Correct Answer - A

Answer- A- Trichuriasis trichiura

It is brown in colour being bile-stained.

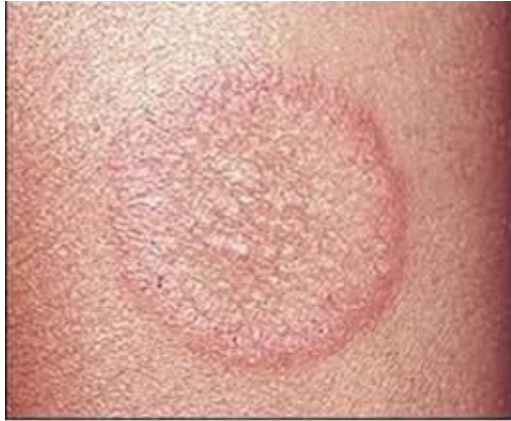It has a triple shell, the outermost layer of which is stained brown.

It is barrel-shaped and about 50 μ m long and 25 μ m wide in the middle, with a projecting mucus plug at each pole containing an unsegmented ovum

The plugs are colourless. The egg floats in the saturated salt solution

Jawetz 27/e-pg-724

262. Identify the organism causing an infection on the upper arm



a) Tinea corporis

b) Tinea capitis

c) Tinea cruris

d) Tinea manus

Correct Answer - A

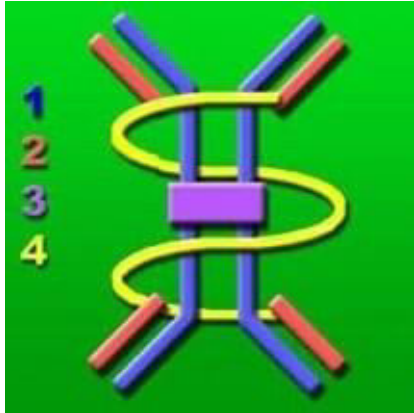
Answer- A- Tinea Corporis.

Dermatophytosis of the glabrous skin commonly gives rise to the annular lesions of ringworm, with a clearing, scaly center surrounded by a red advancing border that may be dry or vesicular.

The dermatophyte grows only within dead, keratinized tissue, but fungal metabolites, enzymes, and antigens diffuse through the viable layers of the epidermis to cause erythema, vesicle formation, and pruritus.

The lesions expand centrifugally and active hyphal growth is at the periphery, which is the most likely region from which to obtain material for diagnosis.

263. Immunoglobulin Image shown below is of-



a) IgA

b) IgG

c) IgM

d) IgE

Correct Answer - A

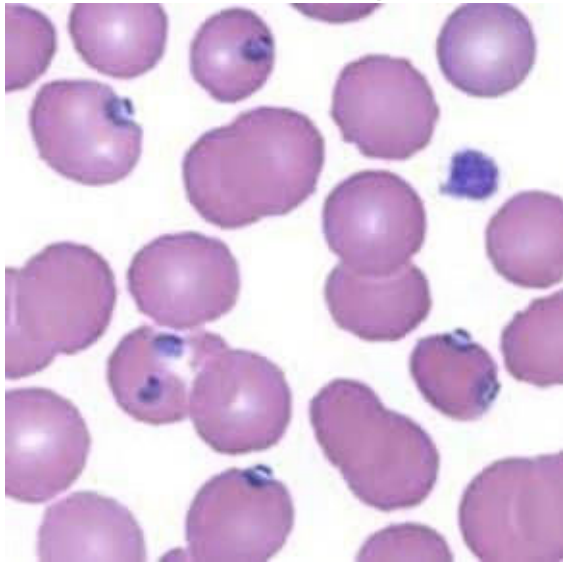
Ans: A. IgA

IgA is the major immunoglobulin responsible for mucosal immunity. The levels of IgA in the serum are low, consisting of only 10–15% of total serum immunoglobulins present. In contrast, IgA is the predominant class of immunoglobulin found in extravascular secretions.

In serum, IgA is secreted as a monomer resembling IgG. In mucous secretions, IgA is a dimer and is referred to as secretory IgA.

This secretory IgA consists of two monomers that contain two additional polypeptides: the J chain that stabilizes the molecule and a secretory component that is incorporated into the secretory IgA when it is transported through an epithelial cell

264. A 15 years old boy presented with fever and chills for 3 days. On examination, he was found to have delayed skin pinch time and dry oral mucosa. A peripheral blood smear revealed the following picture. Identify the pathogen involved?



a) Babesia

b) Plasmodium vivax

c) Plasmodium falciparum

d) Salmonella typhi

Correct Answer - B

Answer- B- Plasmodium falciparum

Given clinical presentation suggestive of malaria.

Double rings in erythrocytes & banana-shaped gametocytes on a

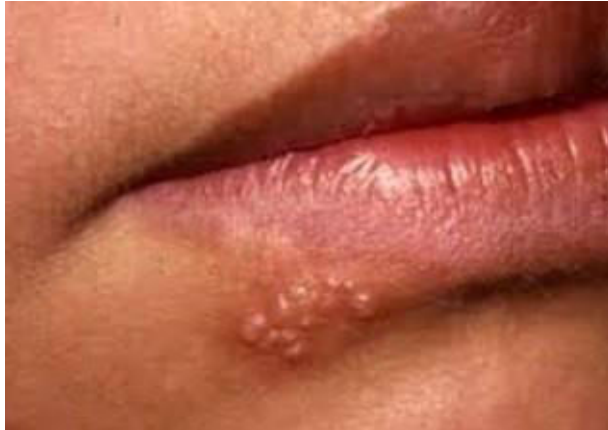peripheral blood smear - typical *P. falciparum* infection.

The early ring form in the erythrocyte is very delicate and tiny, measuring only one-sixth of the red cell diameter. Rings are often seen attached along the margin of the red cell, the so-called form applique or accolé.

Binucleate rings (double chromatin) are common resembling stereo headphones in appearance. Several rings may be seen within a single erythrocyte.

**Paniker's Textbook of Medical Parasitology-8th edition, pg-73;
Jawetz 27/e-medical parasitology-pg-721**

265. A patient complains about painful blisters around the angle of mouth identify the pathogen



a) Herpes Labialis

b) Herpangina

c) Herpes zoster

d) Epstein - Barr

Correct Answer - A

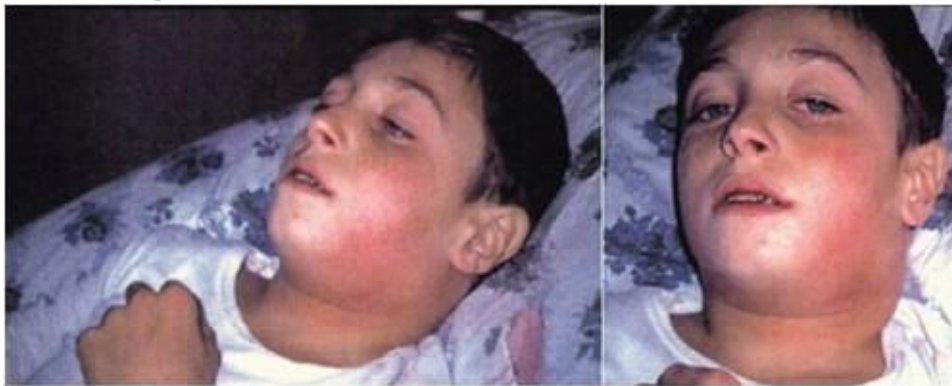Answer- A-Herpes Labialis

Herpes labialis, commonly known as cold sores, is a type of infection by the **herpes** simplex virus that affects primarily the lip. Symptoms typically include a burning pain followed by small blisters or sores. The first attack may also be accompanied by fever, sore throat, and enlarged lymph nodes.

Relapsing infections are limited to the mucosa of the hard palate or, in older children and adults, the lips. The number of relapses decreases after the age of 35 years.

<https://www.ncbi.nlm.nih.gov/pmc/articles/PMC2602638/>

266. A patient with the following feature shown in the image. The patient reports having another 3-year-old sibling at home, who is fully immunized as per the immunization schedule. what is the best measure to prevent diphtheria in the sibling of the diphtheria case child.



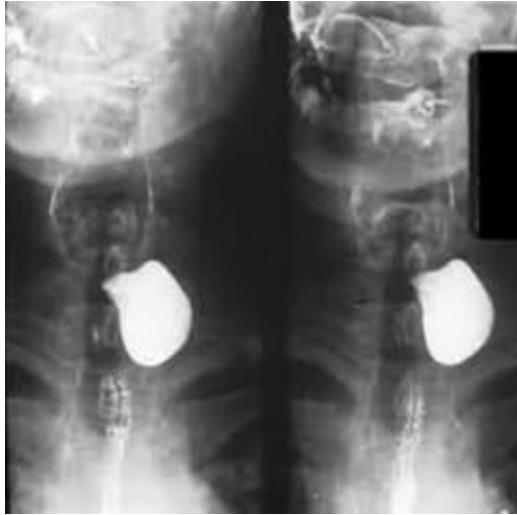
- a) Give diphtheria toxoid booster
- b) Give a full course of DPT vaccine
- c) Give prophylactic erythromycin
- d) Nothing is required to be done

Correct Answer - D

Ans. D. Nothing is required to be done

As per the national immunization protocol, each child receives DPT booster at 16-24 months, and then at 5 years. now as the child in the MCQ is 3 years old and is immunized to date, the child must have received the DPT

267. The most common site of origin of the diverticulum of the pharynx seen in the barium swallow given below is



- a) Between stylopharyngeus and palatopharyngeus
- b) Between middle and inferior constrictor
- c) Between inferior constrictor and esophagus
- d) Between thyropharyngeus and cricopharyngeus

Correct Answer - D

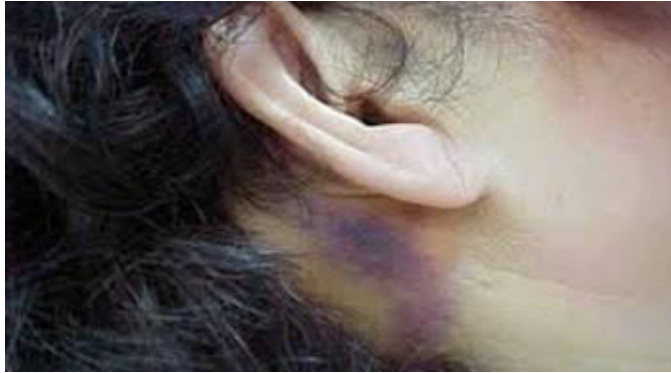Ans:(d) Between thyropharyngeus and cricopharyngeus

The given picture is the barium swallow showing Zenker's diverticulum.

>Zenker diverticulum, a pulsion diverticulum of the hypopharynx, is a rare lesion that occurs in elderly populations. >The condition results in a classic presentation of symptoms, with complications that include aspiration and pneumonia, and is managed by endoscopic and surgical repair.

Ref. Scott BroTon, Vol 3;746

268. Battle sign image Bluish Purple colour behind mastoid?



a) Battle sign

b) Bezold abscess

c) Both A and B

d) None of these

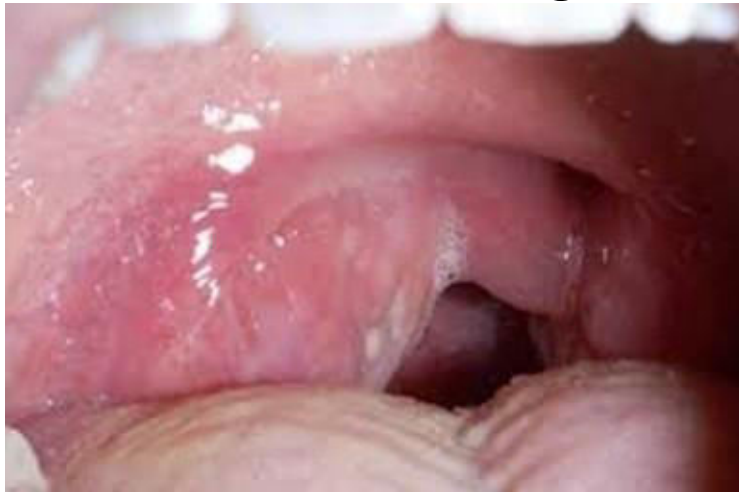Correct Answer - A

Ans. (a) Battle sign.

> Battle Sign (also called Battle's Sign) is defined as bruising over the mastoid process. It is retroauricular or mastoid ecchymosis that is typically the result of head trauma.

ref: https://www.statpearls.com/kb/viewarticle/18169?utm_source=pubmed

269. The patient presents with, fever, dysphagia. Image showing pushing tonsil. what is the diagnosis?



a) Parapharyngeal abscess

b) Retropharyngeal abscess

c) Peritonsillar abscess

d) Ludwig's angina

Correct Answer - C

Ans. C. Peritonsillar abscess

Peritonsillar abscess, also known as quinsy, is the localized collection of pus in peritonsillar space between the tonsillar capsule and superior constrictor muscle.

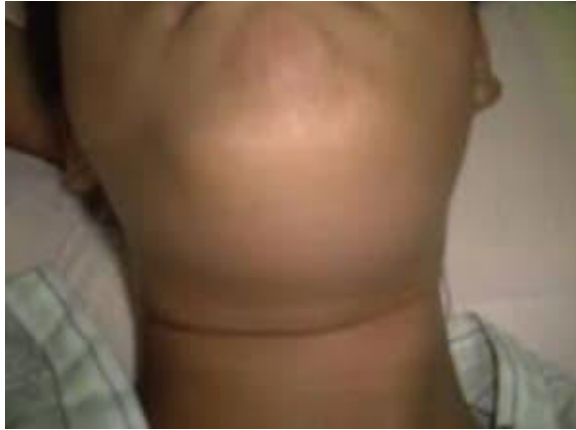>The tonsil is found pushed downward and medially.

>The uvula is swollen and edematous and pushed to the opposite side.

>There is a bulge on the soft palate and anterior tonsillar pillar.

>Mucous may be seen overlying the tonsillar region.

270. This patient gives a history of toothache for one week. What is the diagnosis:



- a) Acute parotitis
- b) Angioneurotic edema
- c) Ludwig's angina
- d) Parapharyngeal abscess

Correct Answer - C

Ans.C. Ludwig's angina

>This is an infection of the submandibular space, i.e. floor of the mouth.

>The most common cause of Ludwig's angina is dental Caries.

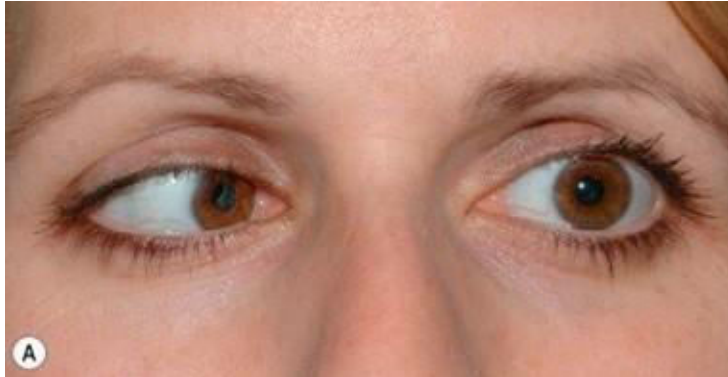>The submandibular space is divided into 2 spaces by the mylohyoid muscle (also known as the oral diaphragm).

>The space above the mylohyoid is known as sublingual space. Here the infection spreads from premolar tooth.

>The space below the mylohyoid is known as submaxillary space laterally and submental space in the center.

>Infection to this space follows carious molars.

271. The movement is lost in:



a) Third nerve palsy

b) Trochlear palsy

c) Sixth nerve palsy

d) Facial nerve palsy

Correct Answer - B

Ans: b. Trochlear palsy

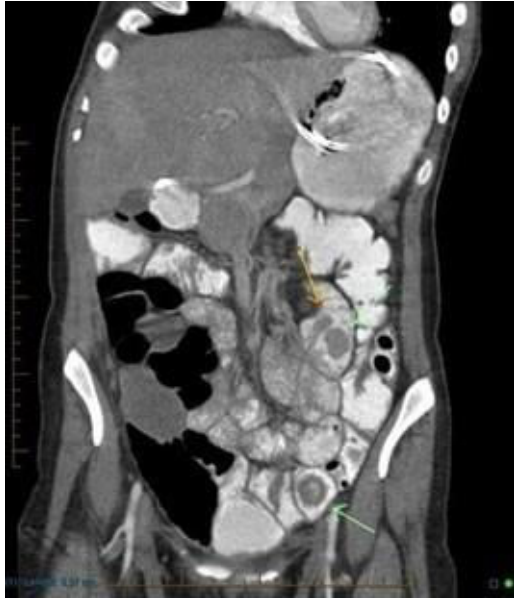>The trochlear nerve is the fourth cranial nerve (CN IV) and one of the ocular motor nerves that control eye movement.

> The trochlear nerve, while the smallest of the cranial nerves, has the longest intracranial course as it is the only nerve to have a dorsal exit from the brainstem.

>It originates in the midbrain and extends laterally and anteriorly to the superior oblique muscle.

Ref: <https://www.ncbi.nlm.nih.gov/books/NBK537244/>

272. Identify the condition given below in the image



a) Peutz jeghers

b) Juvenile polyp

c) Villous adenoma

d) Hyperplastic polyp

Correct Answer - B

Answer- B. Juvenile polyp

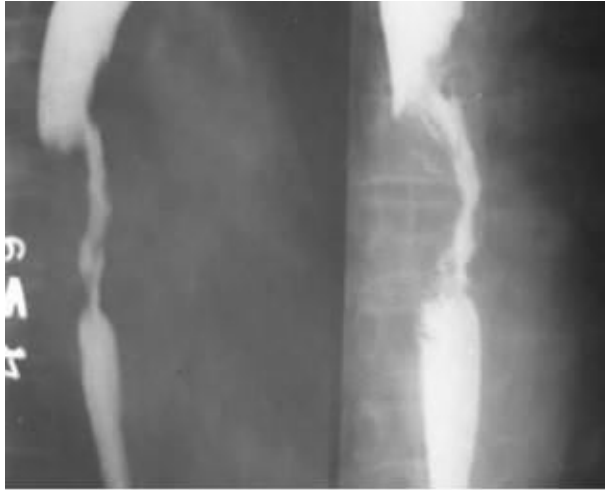The image shown here is Juvenile polyp.

This is a bright red, glistening pedunculated sphere (cherry tumour), which is found in infants and children.

It can cause bleeding, or pain if it prolapses during defecation.

Ref- Bailey and Love, Short practice of surgery, 27th edition published in 2018 Pg 1327

**273. Barium Swallow examination is shown.
What can be the most probable
diagnosis?**



a) Esophageal Ca

b) Esophageal Ring

c) Esophageal Tear

d) Achalasia Cardia

Correct Answer - A

Answer- A. Esophageal Ca

The image is Esophageal carcinoma

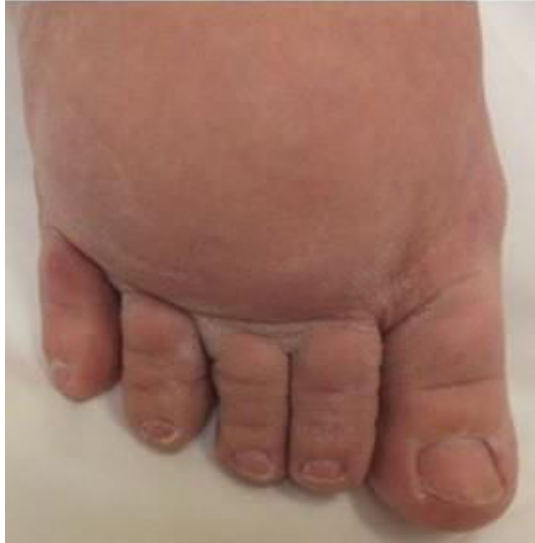Squamous cell cancer and adenocarcinoma are the most common types.

The classic appearance of a mid oesophageal proliferative squamous cell carcinoma.

Squamous cell carcinoma of the esophagus producing an irregular stricture with shouldered margins.

Ref- Bailey and Love, Short practice of surgery, 27th edition

274. Identify the condition given in the image below?



a) Chronic lymphedema

b) Cushing syndrome

c) Osteoporosis

d) None

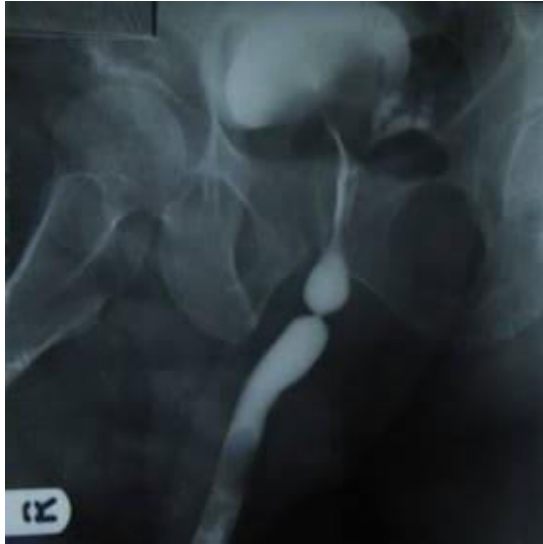Correct Answer - A

Answer- A. Chronic lymphedema

The image shows buffalo hump appearance of the foot seen in chronic lymphedema.

- Lymphoedema characteristically involves the foot.
- The contour of the ankle is lost through infilling of the submalleolar depressions, a 'buffalo hump' forms on the dorsum of the foot, the toes appear 'square' because of confinement of footwear and the skin on the dorsum of the toes cannot be pinched because of subcutaneous fibrosis (Stemmer's sign).

275. Identify the condition given below-



a) MCU with Bulbar urethral stricture

b) MCU with penile stricture

c) RGU with membranous stricture

d) RGU with prostatic stricture

Correct Answer - A

Answer- A. MCU with Bulbar urethral stricture

The common causes of urethral strictures are:

Inflammatory

Secondary to urethritis

Secondary to balanitis xerotica obliterans. (BXO)

Traumatic

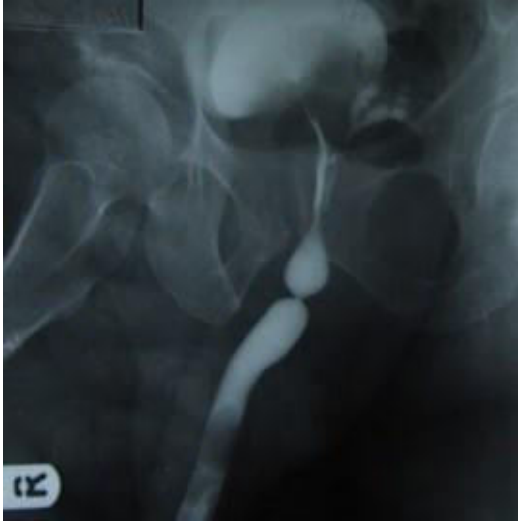Bulbar urethral injury

Pelvic fracture urethral disruption injury

Iatrogenic

Secondary to urethral instrumentation including catheterization and

•
•



276. What is the use of the instrument given in the image below?



a) Laparoscopic sterilisation

b) Removal of ectopic pregnancy

c) Termination of pregnancy

d) Laparoscopic procedures to create pneumoperitoneum

Correct Answer - A

Ans. A. Laparoscopic sterilisation

Lap ring applicator: During a tubal ligation, a 2cm to 3cm segment of the fallopian tube is drawn inside a narrow cone-shaped applicator. The silastic ring previously stretched around the applicator, is then released onto the tubal loop. Once the silastic ring contracts, the fallopian tube is blocked

Ref. <https://www.surgicalinstruments.com/general-lap-bariatric-instruments/fallopian-ring-applicator-for-tubal-ligation>

277. Identify the image below:



a) Female condom

b) Male condom

c) Chaaya

d) Today

Correct Answer - A

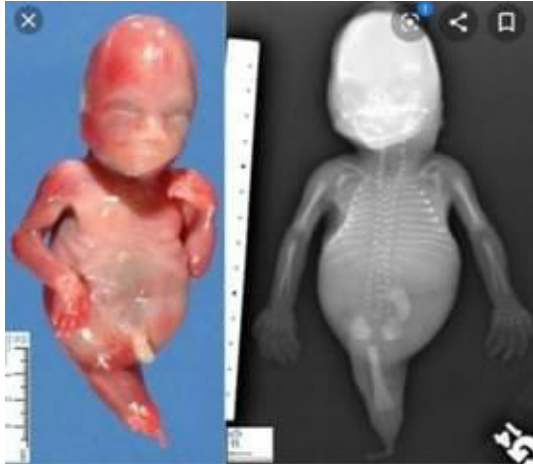Ans. A. Female condom

The female condom (Femidom) :

- It is a pouch made of polyurethane that lines the vagina and also the external genitalia. It is 17 cm in length with one flexible polyurethane ring at each end. The inner ring at the closed end is smaller compared to the outer ring.

Ref. Dutta gynaecology 6th ed. Page no. 476

278. What condition of the mother is associated with the following fetal anomaly?



a) ACE inhibitor

b) GDM

c) Pregestational DM

d) Valproate

Correct Answer - C

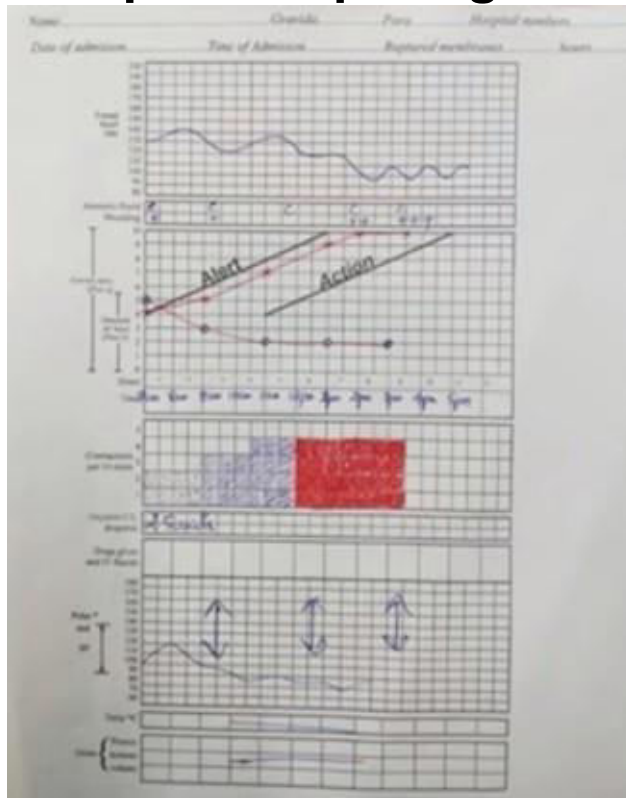
Ans. C. Pregestational DM

The image shows Caudal regression syndrome

This rare anomaly is characterized by the absence of the sacral spine and often portions of the lumbar spine. It is approximately 25 times more common in pregnancies with pregestational diabetes. Sonographic findings include a spine that appears abnormally short, lacks the normal lumbosacral curvature and terminates abruptly above the level of the iliac wings.

Because the sacrum does not lie between the iliac wings, they are

279. Interpret the partogram.



a) CPD

b) Maternal exhaustion

c) Inadequate uterine contractions

d) Rupture uterus

Correct Answer - A

Ans. A. CPD

Patient admitted at 7 AM

Cervical dilatation 4 cm

Head: 5/5th palpable

After 2 hrs

Cervical dilatation: 5 cm

Head: 3/5th palpable

After 4 hrs: 11 AM

Cervical dilatation 7 cm

Head: 2/5th palpable

Cervical dilatation: Reached 10 cm

Uterine contraction is strong after 4 hrs but the Descent of the head is still 2/5th (constant after 4 hrs)

Diagnosis: Arrest of descent

The most common cause of the arrest of descent is cephalopelvic disproportion

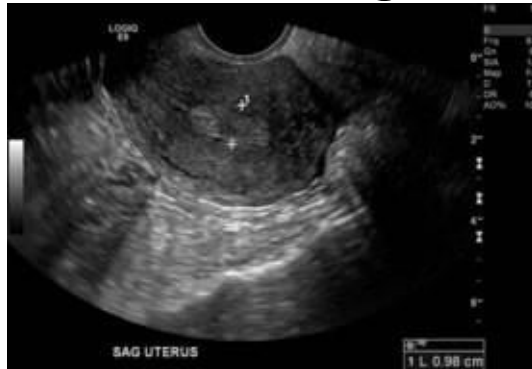Ref. [https://hetv.org/resources/reproductive-](https://hetv.org/resources/reproductive-health/impac/Symptoms/Unsatisfactory__progress_labour_S57_S67.htm)

[health/impac/Symptoms/Unsatisfactory__progress_labour_S57_S67.h](https://hetv.org/resources/reproductive-health/impac/Symptoms/Unsatisfactory__progress_labour_S57_S67.htm) t

https://apps.who.int/iris/bitstream/handle/10665/58903/WHO_FHE_MS

[sequence=1](https://apps.who.int/iris/bitstream/handle/10665/58903/WHO_FHE_MS)

**280. 60 yr female with a history of intermittent bleeding with USG pic shown below.
What is the diagnosis?**



a) Endometrial polyp

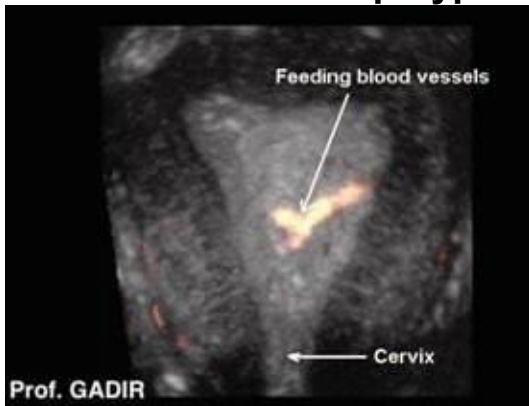
b) Ca endometrium

c) Submucosal fibroid

d) None

Correct Answer - A

Ans A. Endometrial polyp

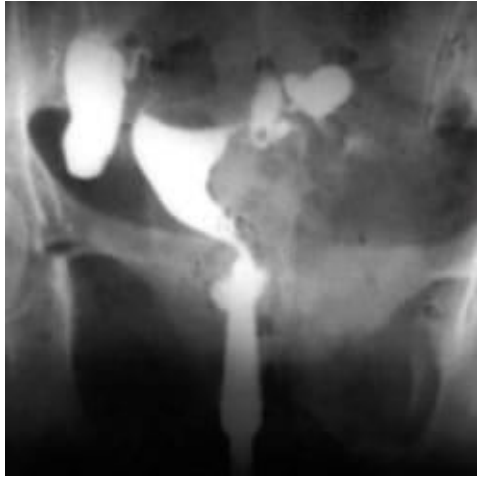

The 3D image gives a better picture of a large vessel passing into a

•

•

281. What will be the Hysteroscopic finding in the given image?



a) Bilateral Hydrosalpinx

b) Bilateral cornual block

c) Normal HSG

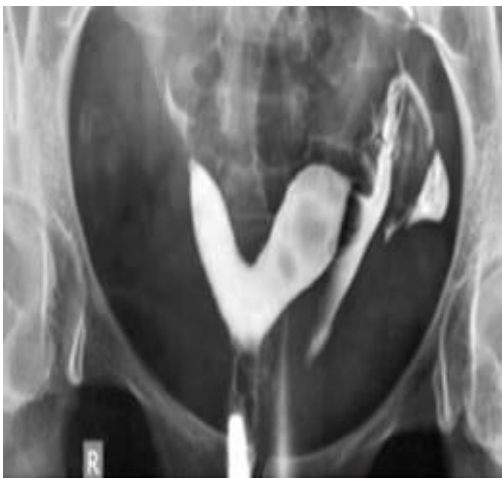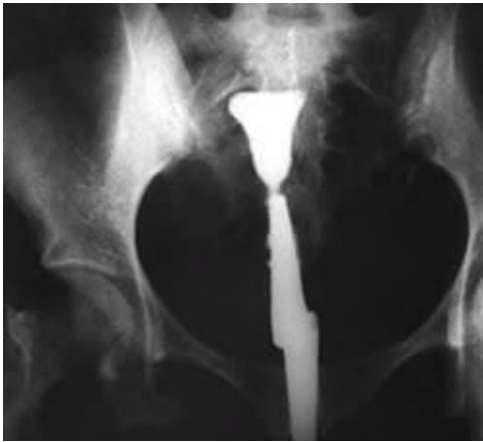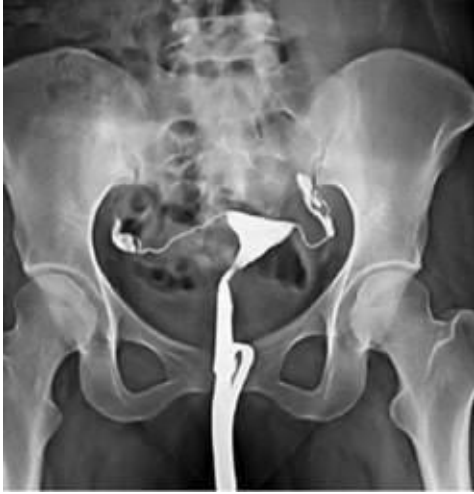d) Bicornuate uterus

Correct Answer - A

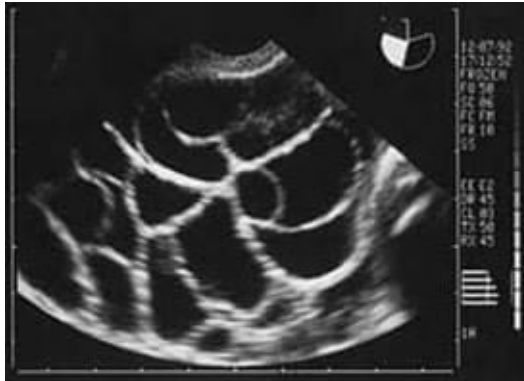Ans. A. Bilateral Hydrosalpinx

The image is Hysterosalpingogram showing bilateral hydrosalpinx (fimbrial block).

Hysterosalpingogram showing radio-opaque shadow filling the uterine cavity. The tubes of both sides are distended with the radio-opaque dye. There is no evidence of peritoneal spillage.



**282. A lady on treatment for infertility developed ascites, abdominal pain & dyspnea.
USG of the patient was done shown below. What will be the diagnosis?**



a) PCOS

b) OHSS

c) Theca lutein cyst

d) Mucinous cystadenomas

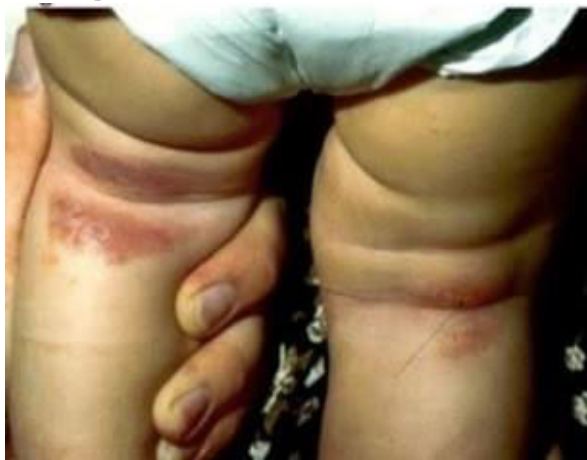Correct Answer - B

ANS. B. OHSS

Ovarian hyperstimulation syndrome (OHSS):

- It is a clinical symptom complex associated with ovarian enlargement resulting from exogenous gonadotropin therapy.
- Symptoms may include abdominal pain and distension, ascites, gastrointestinal problems, respiratory compromise, oliguria, hemoconcentration, and thromboembolism.
- These symptoms may develop during ovulation induction or in early

283. 5-year male child present to the clinic with H/O recurrent infection On examination he was found to have rashes shown below in the image. On routine blood investigation, low platelet count was found what will be the diagnosis?



a) Wiskott Aldrich syndrome

b) Job's syndrome

c) Chediak Higashi syndrome

d) None

Correct Answer - A

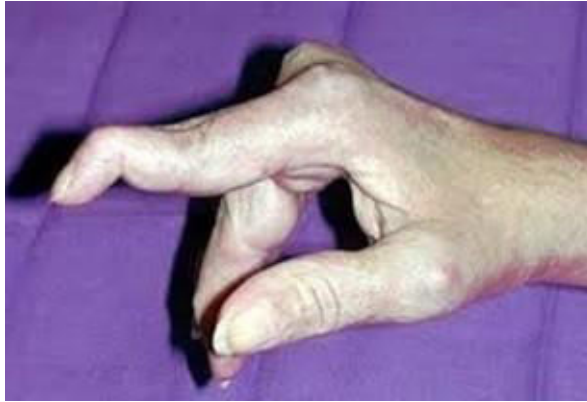Ans. A. Wiskott Aldrich syndrome

Wiskott Aldrich syndrome: There is a mutation in the gene encoding Wiskott-Aldrich syndrome protein (WASP), which is located on Xp11.23. The X-linked disease is characterized by

•

•

284. The patient is presenting with the deformity of the finger as shown. The PIP is involved but the DIP is spared



a) Osteoarthritis

b) Rheumatoid arthritis

c) Psoriatic Arthritis

d) Ankylosing spondylitis

Correct Answer - B

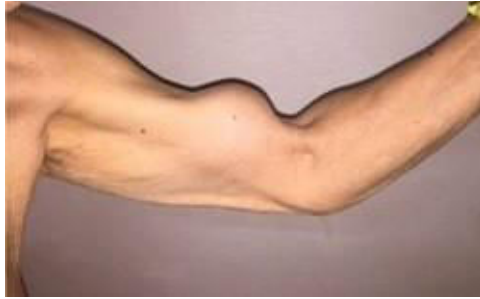Ans: b.Rheumatoid arthritis

>Swan-neck deformity of the finger describes hyperextension at the PIP joint with flexion of the DIP joint

>Rheumatoid Arthritis Clinical Presentation

Ref: <https://www.medscape.com/answers/331715-5365/what-is-a-swan-neck-deformity-of-the-finger-in-rheumatoid-arthritis-ra>

285. What is the most likely diagnosis given in the image -



a) Popeye's sign

b) Griesinger sign

c) Rising sun sign

d) Winner sign

Correct Answer - A

Ans a. Popeye's sign

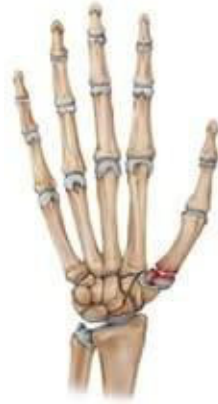>presented to the orthopedic clinic with a large bulge on his right upper arm.

>Examination revealed an obvious deformity in the anterior mid-upper arm that may become more significant during elbow flexion

>This typical finding on physical examination is known as Popeye sign or Popeye deformity, which is caused by bulging of the biceps muscle belly after rupture of the biceps tendon

<https://academic.oup.com/qjmed/article/112/12/931/5487419>

286. The patient is presenting with pain around the base of the thumb, tendons involved -



a) APB & EBL

b) APL & EPB

c) APB & EPB

d) APL & EPL

Correct Answer - B

Ans: b. APL & EPB

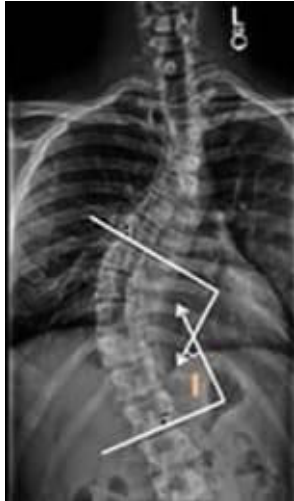>The condition explained in the patient is De Quervain's Tenosynovitis

>De Quervain's Tenosynovitis is a painful inflammation of tendons on the side of the wrist at the base of the thumb.

>These tendons include the extensor pollicis brevis (**EPB**) and the **abductor pollicis longus (APL)**.

>These muscles are located on the dorsal side of the forearm and go to the lateral side of the thumb through a fibrous-osseous tunnel made of the processus styloideus radii and the extensor retinaculum.

287. The shown angle in the image is known as



a) Cobb's angle

b) Bohler's angle

c) Ferguson angle

d) Baumann's angle

Correct Answer - A

Ans: a. Cobb's angle

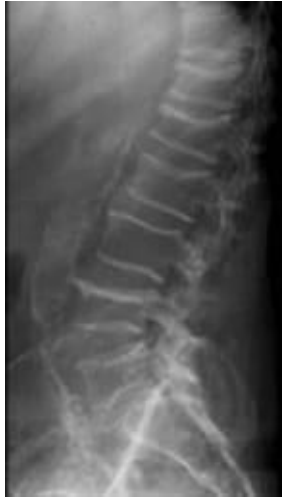>The image shows the Scoliosis pattern in Vertebra.

The Cobb Angle is used as a standard measurement to determine and track the progression of scoliosis.

>The angle of curvature is measured by drawing lines parallel to the upper border of the upper vertebral body and the lower border of the lowest vertebra of the structural curve.

> Then erecting perpendiculars from these lines to cross each other, the angle between these perpendiculars being the 'angle of curvature'

288. What is the diagnosis of 55 old women with a chronic low backache-



a) Osteoporosis

b) Hurler's syndrome

c) Paget's disease

d) Renal osteodystrophy

Correct Answer - A

Ans: a. Osteoporosis

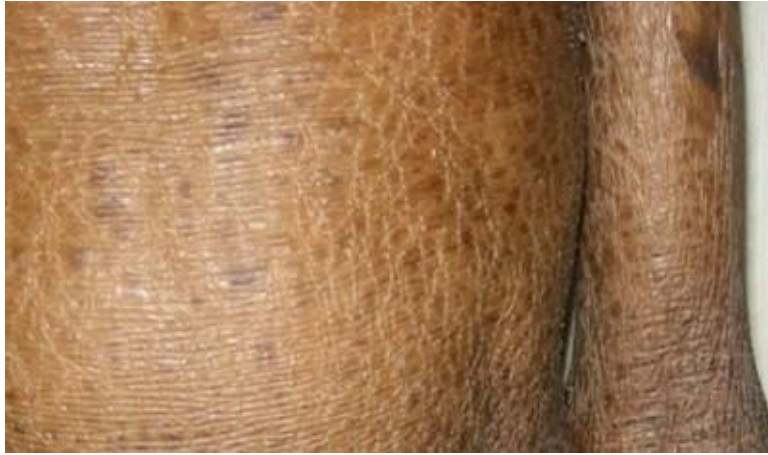>Osteoporosis is, for the most part, a disease of aging.

>The older senior is at high risk for osteoporosis.

>The risk for low bone density increases with age and significantly impacts bone strength.

<https://www.ncbi.nlm.nih.gov/pmc/articles/PMC2685234/>

289. Identify the condition shown in the image?



a) Ichthyosis Vulgaris

b) Syndromal ichthyosis

c) Leprosy

d) Sarcoidosis

Correct Answer - A

Answer- A. Ichthyosis Vulgaris

Ichthyosis is one of the most common genodermatoses. It is characterized by dry (xerotic) scaly skin all over the body. Scales are dull-brown-black. The basic defect is an impairment in the barrier function of skin and inability to maintain moisture.

Ichthyosis can be divided into : -

. Inherited ichthyosis (Ichthyosis Vulgaris, X-linked Ichthyosis, Lamellar ichthyosis, epidermolytic hyperkeratosis).

. Syndromal ichthyosis

. Acquired ichthyosis (Ichthyosis acquisita).

The most common type of ichthyosis is ichthyosis Vulgaris in which

290. The patient came with history of bullae involving >30 % body surface area along with erosions of the lips and other mucosae for the past 7 days. What is the most probable underlying etiology?

☐

a) Bacterial infection

b) Viral infection

c) Drugs

d) Malignancy

Correct Answer - C

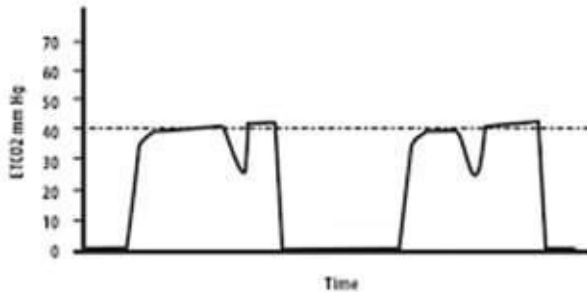
Ans: C. Drugs

Typical of Steven-Johnson syndrome & toxic epidermal necrolysis.

Toxic epidermal necrolysis (TEN):

- Also referred to as "Lyell's syndrome".
- Rare, life-threatening skin condition.
- Usually caused by a drug reaction.

291. Which of the following does the image of Capnograph below depicts?



- a) During inspiration
- b) Inspiration with cardiac oscillations
- c) During expiration
- d) spontaneous respiration

Correct Answer - D

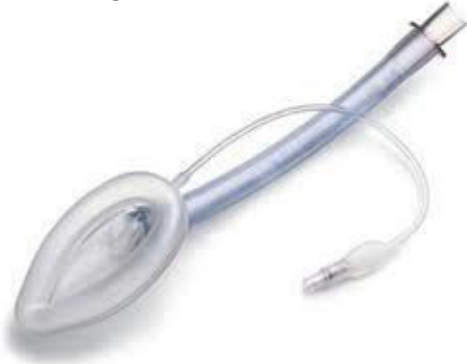Ans. D. spontaneous respiration

The image in the given question shows a capnograph with clefts during phase III which indicates spontaneous breathing efforts by the patient during controlled mechanical ventilation. Also known as **curare notch or cleft**.

Ref: <https://www.ncbi.nlm.nih.gov/pubmed/24132805>

Miller's Anesthesia 8th edition (Page no. 1554)

292. Identify the device shown in the image.



a) Nasopharyngeal Airway

b) Endotracheal Tube(Cuffed)

c) Guedel Airway

d) Laryngeal Mask Airway

Correct Answer - D

Ans:D.)Laryngeal Mask Airway

Laryngeal mask airway

- A type of supraglottic airway.
- It is also referred to as Brain mask as it was invented by Dr. Archies Brain.
- LMA provides an airway intermediate between the face mask and tracheal tube
- It is a medical device that keeps a patient's airway open during anaesthesia or unconsciousness.
- The principle of LMA is that it provides an effective gas-tight seal around the laryngeal inlet without anything having to pass through the vocal cord.
- LMA is very effective in maintaining a patent airway in the spontaneously breathing patient.

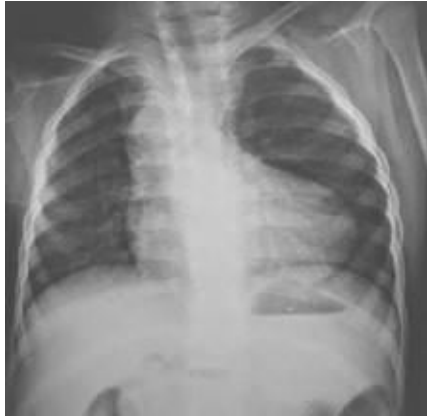•

•

•

•

293. Identify the condition in the X-ray given below-



a) TGA

b) TAPVC

c) TOF

d) Ebstein's anomaly

Correct Answer - C

Answer- C - TOF

The image shown above is of Tetralogy of Fallot condition.

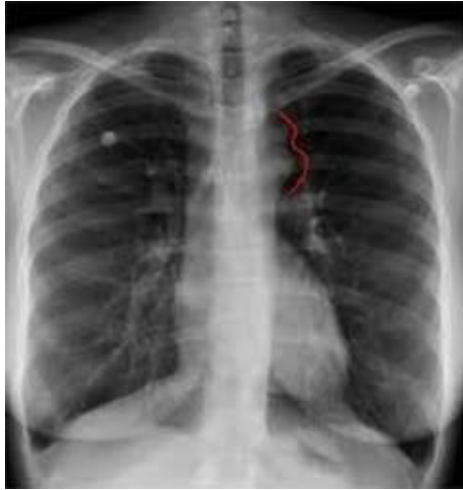Classically the chest radiograph demonstrates a 'boot-shaped' heart with poorly developed lung vasculature.

The diagnosis is confirmed with echocardiography.

Surgery to correct the tetralogy is the mainstay of treatment and is usually carried out at 4-6 months of age, when possible.

Ref- Bailey and Love, Short practice of surgery, 27th edition published in 2018 Pg 905

294. A chest radiograph obtained a male with hypertension. What will be the diagnosis?



a) Tetralogy of Fallot

b) Ebstein's Anomaly

c) TAPVC

d) Coarctation of Aorta

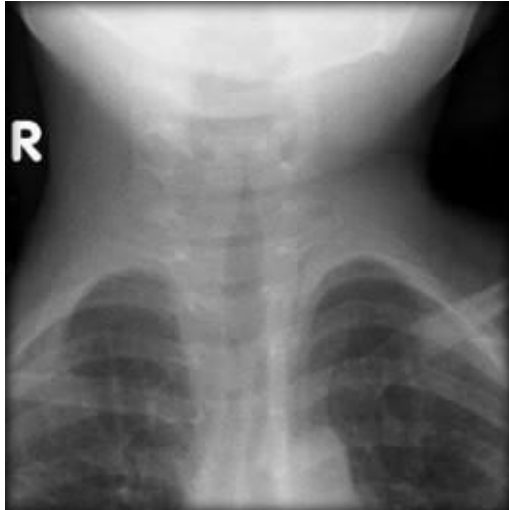Correct Answer - D

Answer- D- Coarctation of Aorta

The chest radiograph classically demonstrates rib-notching because of dilated posterior intercostal vessels. The heart is usually of normal size in the older child and shows a classical 'three sign' replacing the typical aortic knuckle.

Ref- Bailey and Love, Short practice of surgery, 27th edition published in 2018 Pg 906

295. Steeple sign is seen in which of the following condition?



- a) Acute epiglottitis
- b) Acute laryngotracheobronchitis
- c) Laryngeal papillomatosis
- d) Bilateral abductor paralysis

Correct Answer - B

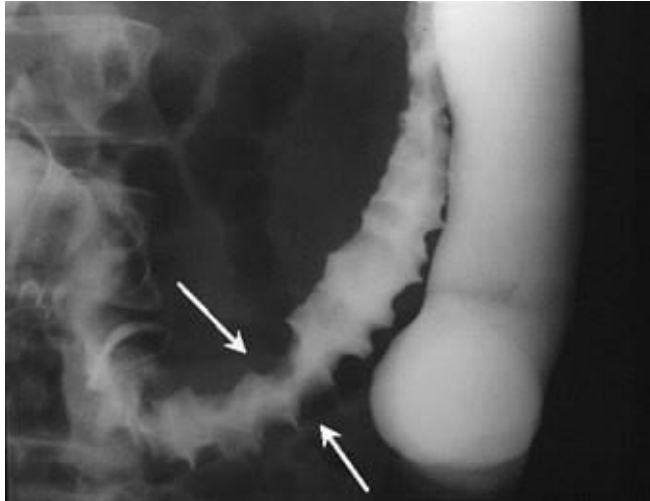
Answer- B- Acute laryngotracheobronchitis

The image below indicates Acute laryngotracheobronchitis. Croup is usually of slower onset than acute epiglottitis and occurs most commonly in children under 2 years of age.

The children have biphasic stridor and are often hoarse with a typical barking cough.

Ref- Bailey and Love, Short practice of surgery, 27th edition published in 2018 Pg 743

296. Identify the radiological sign given below-



a) Diverticulitis

b) Ischaemic colitis

c) Appendicitis

d) None

Correct Answer - B

Answer- B- Ischaemic colitis

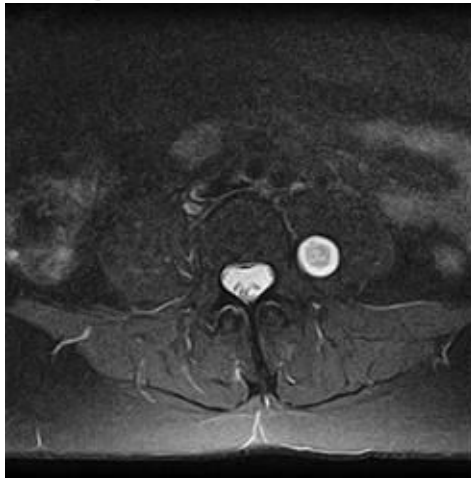Single-contrast barium enema shows the narrowing of the descending colon with a scalloped appearance with ulceration or the classical oedematous 'thumbprinting' sign in ischaemic colitis.

Plain films are frequently taken and often reveal splenic flexure irregularity with a mural thickening.

Ref- David Sutton, Textbook of Radiology and Imaging, Volume 1, Edition 7th, Pg 653

Basic of radiology, Lange, 2nd edition, Pg 642

297. A middle-aged man with a swelling over the neck since childhood with the overlying skin not intact which had a bag or worm-like appearance with a black spot in the middle. What will be the diagnosis?



a) Cirroid aneurysm

b) Varicocele

c) Plexiform neurofibroma

d) Lymphangioma

Correct Answer - C

Answer- C- Plexiform neurofibroma

Plexiform neurofibromas represent an uncommon variant of NF-1 in which neurofibromas arise from multiple nerves as bulging and deforming masses involving also connective tissue and skin folds—hence the clinical description of lesions as “bags of worms.”

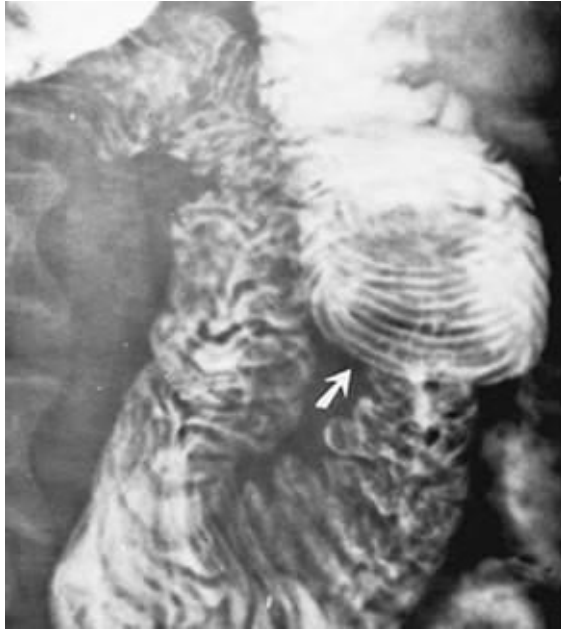
Skin examination also revealed multiple neurofibromas and café-au-lait macules on the trunk and arms.

Ref-

[https://www.ncbi.nlm.nih.gov/pmc/articles/PMC4753888/#!po=35.](https://www.ncbi.nlm.nih.gov/pmc/articles/PMC4753888/#!po=35)

7

298. Identify the radiological image given below-



a) Intussusception

b) Carcinoma colon

c) Sigmoid volvulus

d) Sigmoid volvulus

Correct Answer - A

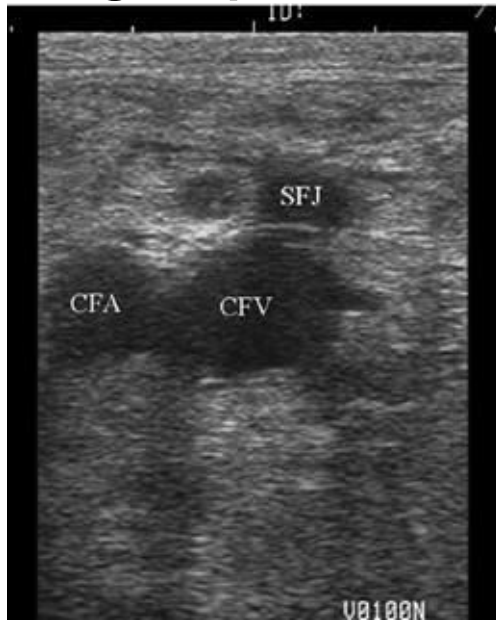Answer- A- Intussusception

This image shows intussusception.

The classic presentation is with episodic abdominal pain and screaming episodes associated with the passage of blood and mucus ('red current jelly').

The abdominal radiograph may demonstrate an absence of bowel gas in the right iliac fossa with a rounded soft-tissue mass a

299. Name the sign seen in the given below image represents-



a) Mickey mouse sign

b) String sign

c) Tillaux sign

d) Stemmer's sign

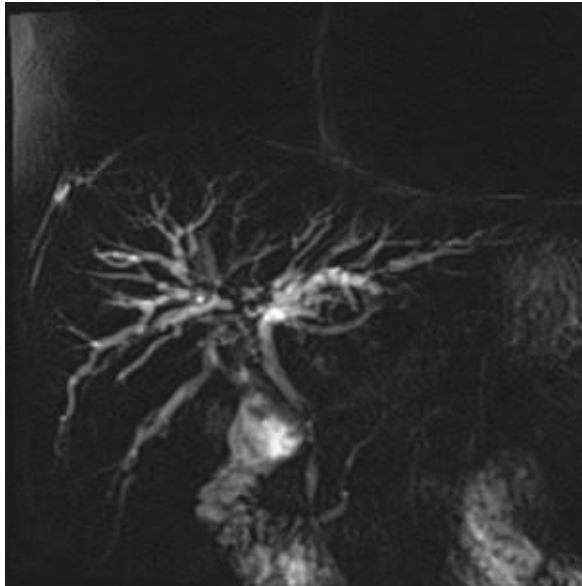
Correct Answer - A

Answer- A- Mickey mouse sign

The Mickey Mouse sign is said to represent the normal anatomy of the common femoral artery, common femoral vein and great saphenous vein on ultrasound at the level just inferior to the inguinal crease.

Reference- Coleridge-Smith P, Labropoulos N, Partsch H, Myers K, Nicolaides A, Cavezzi A. Duplex ultrasound investigation of

300. A 35-year-old male presents with recurrent episodes of abdominal pain, jaundice, and fatigue and underwent MRCP. What will be the most likely diagnosis?



- a) Primary biliary cirrhosis
- b) Caroli's disease
- c) Primary sclerosing cholangitis
- d) Oriental cholangitis

Correct Answer - C

Answer- C- Primary sclerosing cholangitis

This image shows PSC.

MR imaging of the biliary system, especially MRCP, has become more important in biliary imaging, including the detection of calculi of

the gallbladder and biliary tree.

The diagnosis of PSC is principally based on the findings at cholangiography, in which irregular, narrowed bile ducts are demonstrated in both the intrahepatic and extrahepatic biliary tree.

Ref- Bailey and Love, Short practice of surgery, 27th edition published in 2018 Pg 1167

Basic of radiology, Lange, 2nd edition, Pg 313

invalid question id